



## Case Report

# Aseptic osteonecrosis of the humeral trochlea (Hegemann's disease) - a case report

Akira Hara\*

Department of Orthopedic Surgery, Juntendo University Urayasu Hospital, Japan

### ARTICLE INFO

#### Article history:

Received 24 May, 2018

Accepted 4 June, 2018

Published 11 Jun. 18

### ABSTRACT

Aseptic necrosis of trochlea (Hegemann's disease) is very rare. The diagnosis was done only by x-ray. At early stage it is sometimes difficult by X-rays alone to distinguish aseptic necrosis from other conditions, like as osteochondritis dissecans or normal growth ossification center with fragmentation. There is one case report of MRI finding, which was helpful for diagnosis of aseptic necrosis. We report the natural history of aseptic necrosis of trochlea by radiology and confirmed the cure by MRI. We took MRI twice once at the early stage and one after the recovery of aseptic necrosis. Through both radiological and MRI findings, we precisely describe the natural evolution of aseptic necrosis of trochlea

© 2018 Akira Hara. Hosting by Science Repository.

### Introduction

Panner's disease, which is aseptic necrosis of the humeral capitellum, has been reported from time to time. However, aseptic necrosis of the humeral trochlea is extremely rare. This situation was first reported in 1933 by Uhrmacher who discovered this disease in a 7- and a 9-year-old girl, subsequently, Hegemann analyzed the radiographic findings of the elbow in 1200 cases and reported three cases of aseptic necrosis of the humeral trochlea in three boys aged 13, 14 and 16 years [1, 2]. This condition has since been known also as Hegemann's disease. Under observation or by restriction of sports activity this disease is considered to be repaired spontaneously with no sequelae, following the same course as Panner's diseases and a similar course as Perthes' disease. We encountered a 13-year-old boy with Hegemann's disease and reported the natural course as well as radiographic and MR findings.

### Case Report

A 13-year-old boy was referred to our hospital because of pain on medial side of the right elbow while he was serving in tennis (rubber ball)

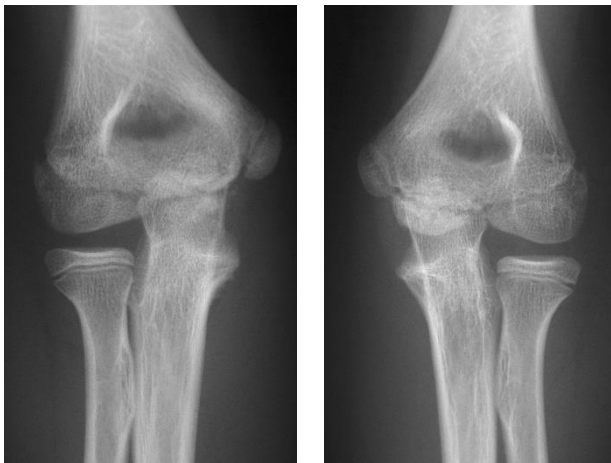
practice, which had started approximately three weeks before his visit. He and his parents (no other people lived with him) had no history of smoking.

At the presentation, there was no resting pain or tenderness in the right elbow. The ranges of motion of the right elbow joint were 10° extension and 140° flexion, with no difference between the left and right sides. The carrying angle was 10°, also with no left-right difference. There was no valgus or Varus instability of the elbow. The patient complained of pain on the medial side when the right elbow was hyperextended during serving action in tennis. A plain radiograph showed the epiphysis had irregularity with fragmentation and loss of density in the right elbow, compared to the unaffected side (Fig. 1). Based on this finding, aseptic necrosis of the humeral trochlea (Hegemann's disease) was highly suspected. MRI taken after 1 month showed low intensity signal in the whole ossification center of the humeral trochlea on T1-weighted images (Fig. 2a) whereas high with iso intensity signal in T2-weighted images (Fig. 2b) indicating ischemic change of the whole trochlea. Then the diagnosis of Hegemann's disease was confirmed.

\* Correspondence to: Akira Hara MD, PhD, Department of Orthopedic Surgery, Juntendo University Urayasu Hospital, 2-1-1 Tomioka, Urayasu-shi, Chiba, 279-0021, Japan, Tel: +81-47-353-3111; Fax: +81-47-390-9881; Email: [hara.a@juntendo-urayasu.jp](mailto:hara.a@juntendo-urayasu.jp)

Sports activity was prohibited, and the patient was followed by observation without external fixation. A radiograph taken after 6 weeks (Fig. 3a) showed that the whole ossific nucleus tended to be flattened and some irregularity remained. At 6 months, the radiograph (Fig. 3b) showed a tendency of regeneration and enlargement of the ossification center, which might indicate the beginning of radiographic repair. Then tennis was permitted but serve actions were prohibited. A radiograph taken 11 months after the first visit (Fig. 3c) showed normal finding of the epiphysis with no difference between the left and right elbows. MRI T1-weighted image and T2-weighted image also showed uniformly high intensity signal in the ossification center of the trochlea (Fig. 4a, b), which indicated complete repair. Serve actions were permitted and the pain during serves disappeared.

### Figures

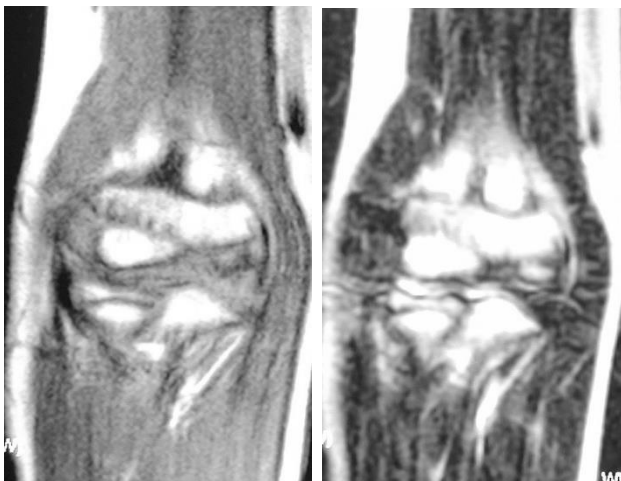


**Fig. 1a.**

**Fig. 1b.**

**Figure 1:** Radiographs on his first visit

- The epiphysis of the trochlea had irregularity with fragmentation and loss of density in the right elbow.
- Left elbow (unaffected side)



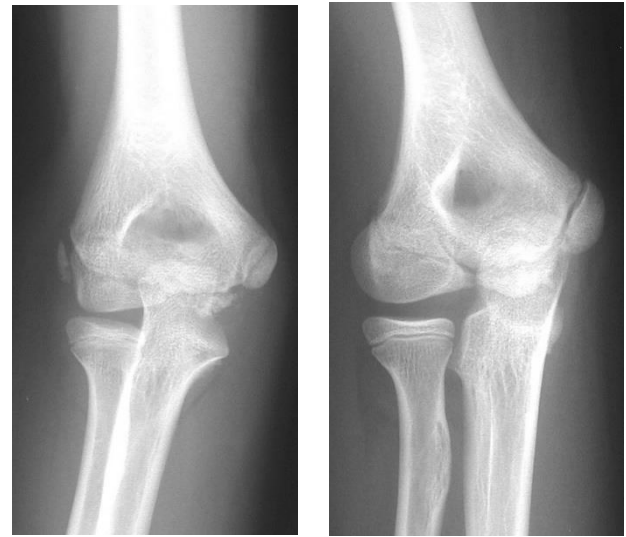
**Fig. 2a.**

**Fig. 2b.**

**Figure 2:** MR images at one month later

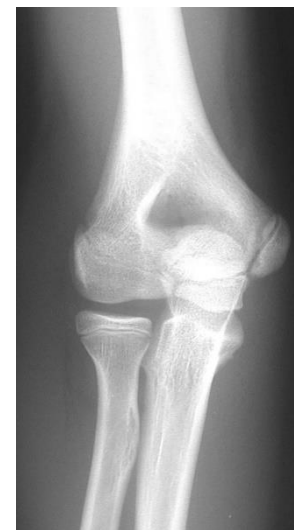- T1-weighted image showed low intensity signal in the whole ossification center of the humeral trochlea.
- T2-weighted image showed high with iso intensity signal in the humeral trochlea.

T1- and T2-weighted images indicated ischemic change of the whole trochlea.



**Fig. 3a.**

**Fig. 3b.**



**Fig. 3c.**

**Figure 3:** The following radiographs.

- A radiograph after 6 weeks showed the whole ossific nucleus tended to be flattened and some irregularity remained.
- A radiograph after 6 months showed a tendency of regeneration and enlargement of the ossification center, which might indicate the beginning of radiographic repair.
- A radiograph after 11 months showed normal finding of the epiphysis with no difference between the left and right elbows.

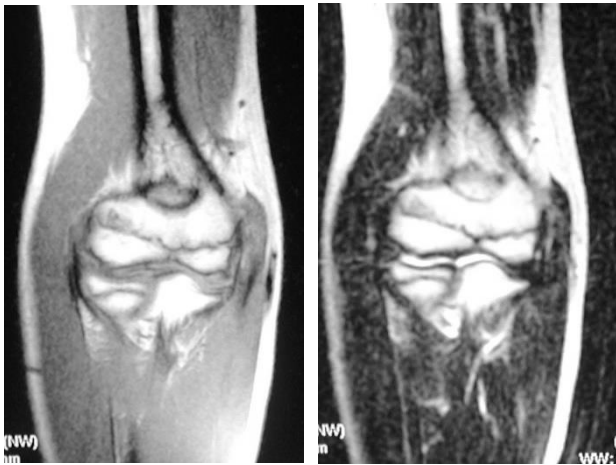

Fig. 4a.

Fig. 4b.

**Figure 4:** MR images at 11 month later.

- a. T1-weighted image showed uniformly high intensity signal in the ossification center, which indicated complete repair
- b. T2-weighted image showed high intensity signal.

### Discussion

Hegemann's disease (aseptic necrosis of the humeral trochlea) is rarer condition than Panner's disease which is aseptic necrosis of the humeral capitellum. The difference in period of appearance of the ossification center is probably one reason for a lower incidence of Hegemann's disease compared to Panner's disease. The period between appearance of the ossification center to closure of the epiphyseal plate is much shorter in the humeral trochlea than in the humeral capitellum. In the ossification process, the ossification center appears in the humeral capitellum at 1 to 26 months after birth, whereas the ossification center appears in the trochlea at 7 to 12 years of age. At 10 to 12 years of age, the capitellum and the trochlea fuse to form one ossification center, followed by bony fusion with the metaphysis of the humerus at 14 to 16 years of age. Therefore, Panner's disease usually occurs in children younger than 10 years, while Hegemann's disease occurs in the age group from 10 years after the ossification center appears to 13-14 years when ossification is completed.

The causes of Hegemann's disease have not been definitely identified but are speculated to be the same as those of Panner's disease, including impaired circulation as a result of minor trauma or repeated stress, and

endocrinological abnormality [3]. In the present case, stress due to repeated serving during tennis playing may be an inducing factor.

Differential diagnoses include normal growth process and osteochondritis dissecans. When the ossification center first appears in the humeral trochlea, it is irregular and sometimes has few ossification nucleus in normal condition. At this stage, it is difficult to differentiate whether the finding is aseptic necrosis of trochlea, normal growth process, or osteochondritis dissecans. Although osteochondritis dissecans is common in humeral capitellum, cases in humeral trochlea were also occasionally reported, which occurred around the time of completion of ossification and might have a poor prognosis with residual deformation [4-6]. Beyer et al demonstrated that aseptic necrosis of the trochlea showed low intensity signal on T1-weighted image of MRI and reported the usefulness of MRI [3]. Usually osteonecrosis is defined as the region of bone marrow with lost signal on both T1- and T2-weighted images, while ischemic changes are designated for areas of bone marrow with patchy, decreased, or absent signal on T1-weighted images but with patchy, iso-intense, or high signal on T2-weighted images. In the present case MRI taken one month after onset showed low intensity in T1-weighted and high intensity in T2 weighted image indicate ischemic change of ossification center. MRI was also conducted in addition to radiography and helped confirmation both of a diagnosis of osteonecrosis and of recovery. MRI was thus useful in diagnosis of Hegemann's disease and also in verification of recovery

### REFERENCES

1. Uhrmacher F (1933) ber Osteochondritis deformans juvenilis des Ellbogengelenkes. *Z Orthop Chir* 59: 398-411.
2. Hegemann G (1951) Die "spontanen", aseptischen Knochennekrosen des Ellenbogengelenkes. *Fortschr Rontgenstr* 75: 89-92.
3. Beyer WF, Heppt P, Glckert K, Willauschus W (1990) Aseptic osteonecrosis of the humeral trochlea (Hegemann's disease). *Arch Orthop Trauma Surg* 110: 45-48. [[Crossref](#)]
4. Joji S, Murakami T, Murao T (2001) Osteochondritis dissecans developing in the trochlea humeri: a case report. *J Shoulder Elbow Surg* 10: 295-297. [[Crossref](#)]
5. Patel N, Weiner SD (2002) Osteochondritis dissecans involving the trochlea: report of two patients (three elbows) and review of the literature. *J Pediatr Orthop* 22: 48-51. [[Crossref](#)]
6. Vanthournout I, Rudelli A, Valenti P, Montagne JP (1991) Osteochondritis dissecans of the trochlea of the humerus. *Pediatr Radiol* 21: 600-601. [[Crossref](#)]