

Available online at www.sciencerepository.org

Science Repository



Case Report and Review of the Literature

Bilateral Carotid Body Tumor Treated with Primary Radiotherapy and Resected Subsequently: Report of a Case and Review of the Literature

Luis Pacheco-Ojeda^{1*}, Xavier Jarrín-Estupiñán², Montalvo-Burbano Mario³ and Elba Salazar⁴

¹Otorhinolaryngology and Head and Neck Surgery Service, Social Security Hospital, Quito, Ecuador

²General Surgery Service, Vozandes Hospital, Quito, Ecuador

³General Surgery Service, Metropolitano Hospital, Quito, Ecuador

⁴Pathology Service, Social Security Hospital, Quito, Ecuador

ARTICLE INFO

Article history:

Received: 17 April, 2020

Accepted: 1 June, 2020

Published: 25 June, 2020

Keywords:

Carotid body

tumor radiotherapy

post-irradiation surgery

ABSTRACT

Carotid body tumors (CBT) are rare benign neoplasms of neural crest origin arising from paraganglia cells located at carotid bifurcation. They are usually treated with surgery and occasionally with radiotherapy (RT) as a definitive treatment. We report a case of a carotid body tumor (CBT) in a 45-year old woman who was treated with RT at another institution with intent of diminishing its size and eventually be operated later. This tumor, located on the left side of the neck, appeared 3 years before and was associated with dysphagia and odynophagia. A computed tomography (CT) revealed a lesion of 4.7 cm in size. The patient received 54 Gy of RT. As the tumor persisted clinically, an angio-CT performed one year later showed a left CBT of the same size and a contralateral lesion of 2cm. The surgical resection of this smaller right lesion was performed first and, of the persistent left lesion, one month later. No technical difficulties were found on the resection of the latter tumor and rather decreased peripheral vascularization was present. The histological findings revealed changes due to RT. In an exhaustive review of the literature, there were no findings of any report of surgical resection of a CBT after the primary RT.

© 2020 Luis Pacheco-Ojeda. Hosting by Science Repository.

Introduction

The carotid body tumor (CBT) are rare neoplasms with greater incidence in high altitude regions [1, 2]. They are located in the adventitia, posteromedially to the bifurcation of the common carotid artery and arise from embryonic neuroepithelium. They are asymptomatic, slowly growing, hypervascularized, laterally mobile neck masses, under the angle of the jaw. These occur more frequently in female patients in the fourth to sixth decades of life. Malignancy has been reported in about 3% of cases. Doppler ultrasound and angio-CT offers practically a 100% of certain diagnosis [3]. Surgical resection is the treatment of choice. It is currently safe and postoperative morbidity is low. Radiotherapy (RT) can be used as a definitive treatment or in patients whose medical conditions contraindicate surgery or refuse surgery.

This is a report of an unusual case, not previously described in the literature, of a patient with the bilateral CBT, one of which was treated with definitive RT in another institution and subsequently underwent bilateral surgery.

Case Report

A 45-year old woman attended another institution for a CBT located on the left side of the neck, that had appeared 3 years before and was associated to dysphagia and odynophagia. A computed tomography (CT) revealed a lesion of 4.7 cm of size. The patient received 54 Gy of radiotherapy (RT) with linear particle accelerator with the intent to reduce its size and eventually to proceed to a surgical resection later. As

*Correspondence to: Luis Pacheco-Ojeda, Otorhinolaryngology and Head and Neck Surgery Service, Social Security Hospital, Sarmiento de Gamboa Oe 5-38, Quito, Ecuador; E-mail: luispacheco.o@hotmail.com

the tumor persisted clinically, an angio-CT, performed one year later, showed a left CBT of the same size and a contralateral lesion of 2cm (Figures 1 & 2). The surgical resection of this smaller right lesion, Shamblin I, was performed initially. The resection of the second persistent left lesion was done one month later. The absence of the typical peripheral hypervascularization, that CBT usually present, called the attention to us. In addition, peritumoral fibrosis did not exist and the dissection of the carotid vessels was performed without any particular difficulty. A level III routine lymph node dissection was done on both sides. The histological diagnosis was a paraganglioma, with extended areas of fibrosis, some of them with necrosis, necrotized diffuse haemorrhages, vasculopathy, ectasia and reduction of the tumor cellularity; these findings was supposed to be due to changes by radiation. The histochemical analysis was positive for neuron specific enolase, chromogranin, synaptophysin, galanin and serotonin (Figures 3-5). Lymph nodes were negative for malignancy.

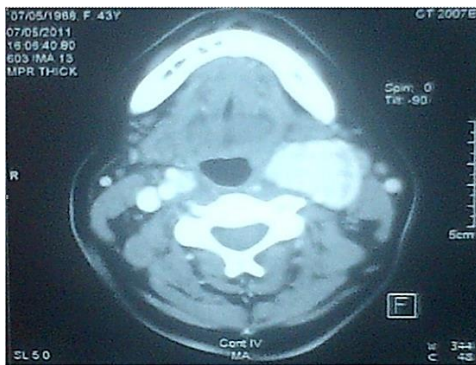

Figure 1: Simple and contrast CT shows a persistent left CBT and a very small right CBT.

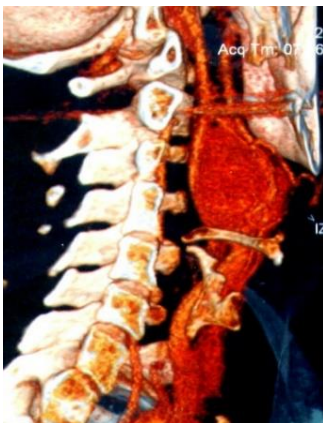

Figure 2: Angio-CT of the left persistent CBT.

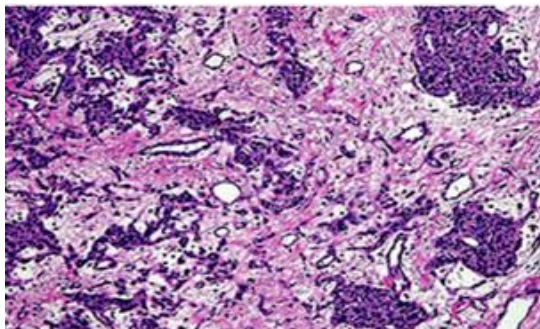


Figure 3: Histopathological view of irradiated left CBT (lens 20x).

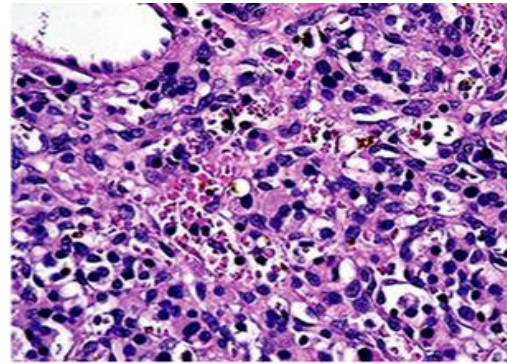


Figure 4: Haematoxylin and eosin staining. Round and cuboid glomic cells with scarce cytoplasm (zellballen) (lens 40x).

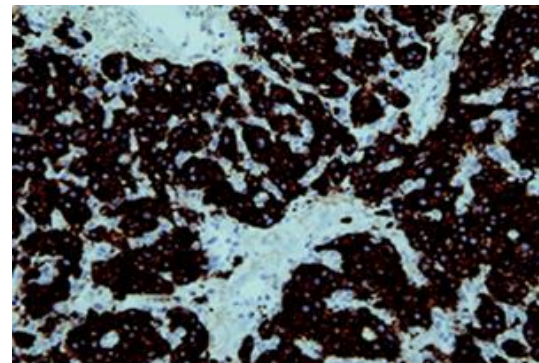


Figure 5: Immunohistochemistry: Positive chromogranin in glomic cells (lens 40x).

Discussion

The treatment of choice for CBT is surgical resection [2, 4-6]. However, this therapeutic option cannot be applicable in great, technically unresectable tumors, in high risk patients, with comorbidities, or in patients of advanced age. In these cases, an active surveillance or RT could be chosen [7]. In a US nationwide study of 684 CBT, 573 were surgically treated but no type of therapy was mentioned for the rest of patients [8]. In another nationwide study from China, all of the 1810 patients were surgically treated [9].

Few series of primary treatment of CBT with irradiation have been reported [10-14]. Because of the morbidity of the surgical treatment, mainly, occasional central nervous system neurological complications or cranial nerve injuries, RT could be an acceptable alternative. Complete tumor disappearance, shrinking or stabilization of size have been described after long term follow up with a minimum risk of morbidity and toxicity. Local control, similar to surgery, as high as 92% at 5 years, has been reported. Recommended RT dose for the CBT is similar to that one used for chemodectomas of the temporal bone, that is to say, 4500 cGy, divided in 25 doses, with continuous course technique.

We have not found any case of irradiated CBT and resected subsequently in the medical literature. The resection possibility after RT has not been mentioned. Tosun recently reported 12 patients with head and neck paragangliomas, six of which were CBT [15]. All of them received fractionated stereotactic radiotherapy with CyberKnife® up to a total median dose of 24 Gy. There was no acute or late toxicity related with stereotactic radiotherapy. After a median follow up of 30 months,

seven tumors shrunk in size (54%) and five tumors (46%) had stable size. Local control rate was 100%. Our surgical experience includes 230 resected CBT and 25 tumors non-operated for comorbidities or advanced age. Among the last group of patients, only two were irradiated. The first of them had 20% reduction in size after treatment, and the second, 5%.

Our patient was treated, in another institution, for an apparently resectable CBT but she preferred RT with the intention of reduction of the tumor size. When she came to our service, the tumor was palpable and the angio-CT showed a CBT whose size was seemingly the same as before radiation treatment. It appeared to us that the lesion was susceptible of resection. Surprisingly, a contralateral small CBT was found in this study. Tumor stabilization of the irradiated lesion could have occurred but she preferred, this time, a surgical procedure of both tumors to avoid close clinical controls in the future otherwise.

In case of bilateral CBT, staged resection is preferred but which lesion, the smaller or the bigger, to operate first is controversial. We decided to resect the smaller tumor initially to make sure that this surgery would not cause any injury of the IX, X and XII cranial nerves that in case of being bilateral, would have been absolutely disabling.

During the operation, we noticed reduced peripheral vascularization of the tumor probably due to RT. Fortunately; we did not have any technical difficulties to dissect the tumor free from the carotid vessels. From the pathological point of view, the paraganglioma presented histological characteristics related to the previous radiation treatment.

Conclusion

According to this surgical experience, we can conclude that resection of an irradiated CBT is feasible without any additional surgical technical difficulty and, secondly, that apparently, the irradiation decreases the peripheral vascularization of the tumor without any particular fibrotic tissue found in the surgical area.

REFERENCES

- Rodríguez Cuevas S, López J, Labastida S (1998) Carotid Body Tumors in Inhabitants of Altitudes Higher Than 2000 Meters Above Sea Level. *Head Neck* 20: 374-378. [[Crossref](#)]
- Pacheco Ojeda LA (2017) Carotid Body Tumors: Surgical Experience in 215 Cases. *J Craniomaxillofac Surg* 45: 1472-1477. [[Crossref](#)]
- Pacheco Ojeda L, Martínez MA (2010) Preoperative Imaging Diagnosis of Carotid Body Tumors. *Int Surg* 95: 242-246. [[Crossref](#)]
- Sánchez De Guzmán G, Espinel Ortiz C, Camacho Makenzie J (2008) Paragangliomas de cuerpo carotideo: clasificación y manejo de 143 tumores. *Acta de Otorrinolaringología Cirugía de Cabeza y Cuello* 36: 109-116.
- Davila VJ, Chang JM, Stone WM, Fowl RJ, Bower TC et al. (2016) Current Surgical Management of Carotid Body Tumors. *J Vasc Surg* 64: 1703-1710. [[Crossref](#)]
- Kim GY, Lawrence PF, Moridzadeh RS, Zimmerman K, Munoz A et al. (2017) New Predictors of Complications in Carotid Body Tumor Resection. *J Vasc Surg* 65: 1673-1679. [[Crossref](#)]
- Barrera Franco JL y cols (2000) El manejo de los paragangliomas en el Instituto Nacional de Cancerología. *Rev Inst Nal Cancerol (Mex)* 46: 17-20
- Dua A, Spees T, Hernandez F, Igbadumhe AA, Algodí M et al. (2014) Trends in the Incidence of Carotid Body Tumors in the United States from 1998 to 2011. *Vasc DisManag* 11: E298- E302.
- Chen Y, Li Y, Liu J, Yang L (2020) The Clinical Characteristics and Outcomes of Carotid Body Tumors in Chinese Patients: A STROBE-compliant Observational Study. *Medicine (Baltimore)* 99: e18824. [[Crossref](#)]
- Valdagni R, Amichetti M (1990) Radiation Therapy of Carotid Body Tumors. *Am J Clin (CCT)* 13: 45-48. [[Crossref](#)]
- Guedea F, Mendenhall WM, Parsons JT, Million RR (1991) Radiotherapy for Chemodectoma of the Carotid Body and Ganglion Nodosum. *Head Neck* 13: 509-513. [[Crossref](#)]
- Vermiers DA, Keus RB, Schowenburg PF, Bartelink H (1992) Radiation Therapy, an Important Mode of Treatment for Head and Neck Chemodectomas. *Eur J Cancer* 28: 1028-1033. [[Crossref](#)]
- Evenson LJ, Mendenhall WM, Parsons JT, Cassisi NJ (1998) Radiotherapy in the Management of Chemodectomas of the Carotid Body and Glomus Vagale. *Head Neck* 20: 609-613. [[Crossref](#)]
- Hinerman RW, Amdur RJ, Morris CG, Kirwan J, Mendenhall WM (2008) Definitive Radiotherapy in the Management of Paragangliomas Arising in the Head and Neck: A 35-year Experience. *Head Neck* 30: 1431-1438. [[Crossref](#)]
- Tosun İ, Atalar B, Şahin B, Güngör G, Aydın G et al. (2018) Robotic Radiosurgery of Head and Neck Paragangliomas: A Single Institution Experience. *Asia Pac J Clin Oncol* 14: e3-e7. [[Crossref](#)]