

Available online at [www.sciencerepository.org](http://www.sciencerepository.org)

Science Repository



## Case Report and Review of the Literature

# Modified Charles Procedure for Tissue Destruction after Gluteal Silicone Injection in a Transgender Woman

*Philip S Brazio*<sup>1\*</sup>, *Smita Mascharak*<sup>2</sup>, *Andrew B Siref*<sup>3</sup>, *Thomas M Hagopian*<sup>1</sup> and *Edward C Ray*<sup>2</sup>

<sup>1</sup>Division of Plastic and Reconstructive Surgery, University of Southern California

<sup>2</sup>Division of Plastic and Reconstructive Surgery, Cedars-Sinai Medical Center

<sup>3</sup>Department of Pathology, Cedars-Sinai Medical Center

### ARTICLE INFO

#### Article history:

Received 13 August, 2018

Accepted 4 September, 2018

Published 10 October 2018

#### Keywords:

*Liquid injectable silicone*

*Complications*

*Transgender*

*Gender-affirming surgery*

*Charles procedure*

### ABSTRACT

A 49-year-old male-to-female transgender patient presented to the Emergency Department with inflammation and soft tissue necrosis of the right leg. She had undergone injection of liquid silicone into her buttocks and hips for cosmetic purposes five years prior, causing several episodes of infection and long-standing open wounds over the buttocks and both lower extremities. Limited debridement, antibiotics, and local wound care did not halt the slow progression of tissue loss. Radical dermofasciectomy of the right leg was performed, followed by split thickness skin grafting from the back. The grafts healed well and the patient regained full leg function.

Large volume injection of industrial-grade liquid silicone is an unfortunately common practice, often used by unlicensed racketeers in feminization procedures. Devastating complications may occur well away from the zone of injection. As gender affirming procedures become more prevalent, so does the potential for complications associated with the inappropriate use of liquid silicone injection. Early recognition of these complications can allow the institution of appropriately aggressive therapy. In a scenario of widespread infectious and inflammatory damage to soft tissues of the limb, wide dermofasciectomy with split thickness skin grafting should be considered as an option for limb salvage.

© 2018 Philip Brazio. Hosting by Science Repository.

### Case Presentation

A 49-year-old male-to-female transgender patient presented to the Emergency Department with one day of pain, swelling, and redness of the right leg. She had undergone injection of liquid silicone into her buttocks and hips for cosmetic purposes outside the United States five years prior. Since then the material had migrated to more dependent regions in the subcutaneous plane, causing widespread foreign-body reaction and a series of recurrent open wounds which subsequently became infected. These were conservatively managed with local wound care.

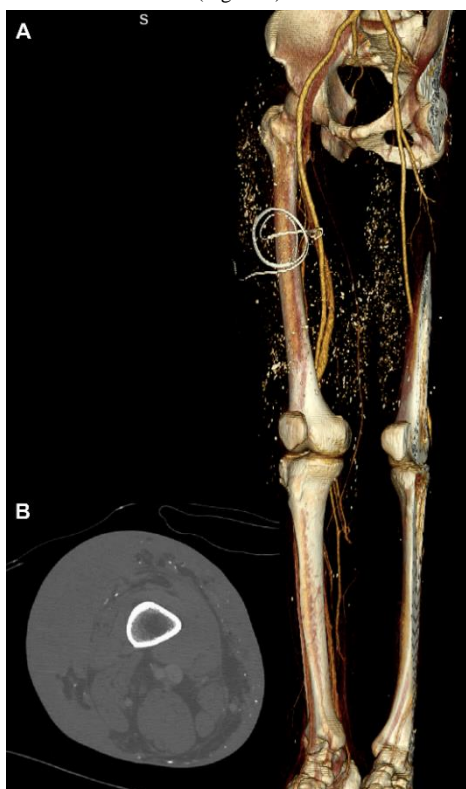During this latest episode, the patient was admitted for cellulitis and concern for compartment syndrome presenting with extensive swelling

and induration. Computed tomography revealed extensive subdermal tissue infiltration and diffuse granuloma formation with calcification from buttocks to feet bilaterally, with sparing of the muscular compartments (Figure 1). She underwent decompressive fasciotomy of the affected leg, which did not reveal muscle edema or myonecrosis. The wounds did not improve with broad-spectrum antibiotics and local wound care. Instead the leg and foot underwent further wound breakdown and epidermolysis (Figure 2). The option of below-knee amputation to prevent sepsis and further spread of infection was discussed with the patient, but she refused.

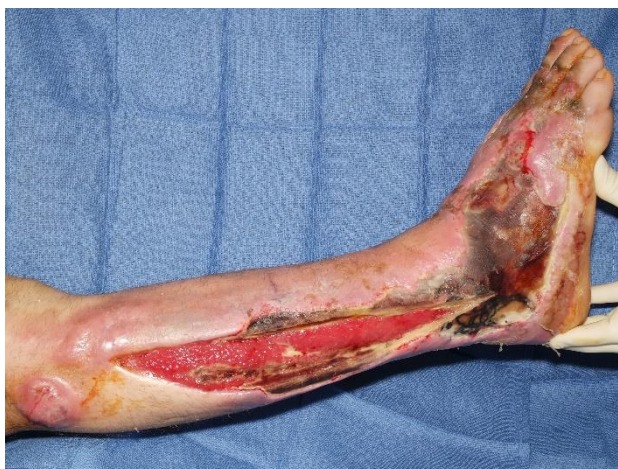The Plastic Surgery service was consulted for wound management. The option of limb salvage through radical debridement and staged skin grafting was then offered. She underwent resection of all skin and

\*Correspondence to: Philip Brazio, MD, Division of Plastic Surgery, Keck School of Medicine of USC 1510 San Pablo Street, Suite 415, Los Angeles, CA 90033; Tel: +323-442-7903; Fax: +323.442.7901; Email: [braziomd@gmail.com](mailto:braziomd@gmail.com)

subcutaneous tissue below the knee, sparing the plantar surface and toes, followed by negative pressure wound therapy. Pathology showed ulceration, extensive fibrosis, deep tissue necrosis, and numerous cystic spaces, some containing amorphous, refractile foreign material, compatible with silicone (Figure 3). No bacterial or fungal elements were identified within the tissues, and tissue cultures were negative. Five days after resection, the patient underwent meshed split thickness skin grafting of the affected area from donor sites on the back. The graft had nearly 100% take and, following a period of rehabilitation, the patient was able to ambulate (Figure 4).



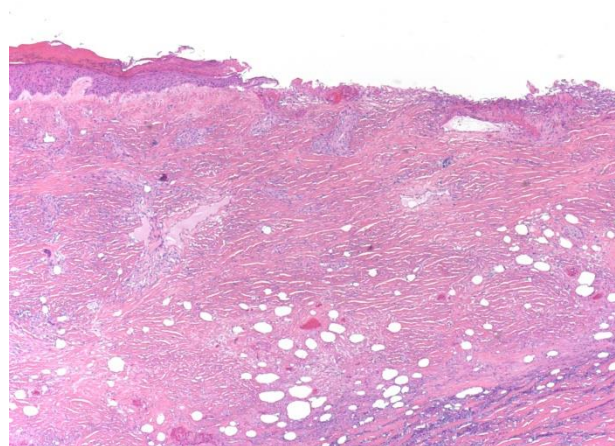
**Figure 1.** Computed tomography (a) three-dimensional reconstruction and (b) axial slice showing extensive lower extremity subcutaneous tissue infiltration with calcified granulomas and obliteration of fat, and sparing of muscular compartments.



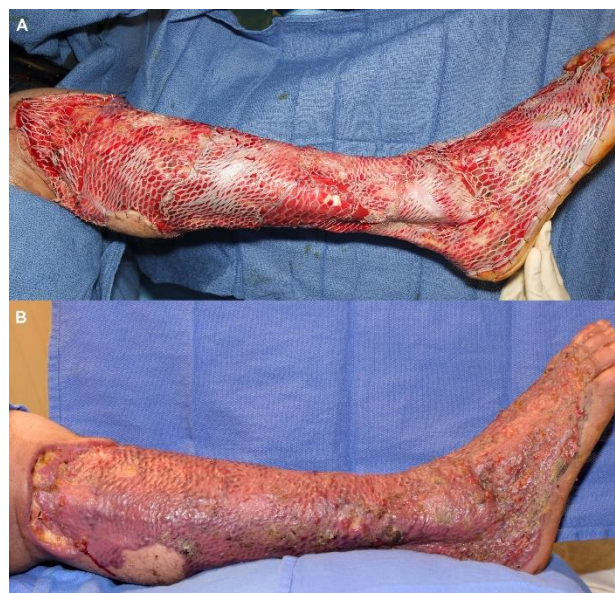**Figure 2.** Epidermolysis of chronically fibrotic and inflamed skin after silicone injection.

## Discussion and Review of the Literature

Although silicone injection as a soft tissue filler was first described in the medical literature in 1963, it was first used following World War II, outside the norms of medical practice [1-3]. Dow Corning 200 transformer insulating fluid, diverted from the docks at Yokohama harbor, was injected by unlicensed practitioners into the breasts of Japanese prostitutes. A mixture of the non-sterile fluid with vegetable oil was brought by a Japanese osteopath to Beverly Hills and popularized over the next two decades [2]. Only one year following initial reports, a 1964 case series first demonstrated the potential of silicone injection to cause local inflammation, granulomas and tissue necrosis [4].



**Figure 3.** Ulceration, extensive fibrosis, deep tissue necrosis, and numerous cystic spaces, some containing amorphous, refractile foreign material, compatible with silicone.



**Figure 4.** Split thickness skin grafting of right lower leg, (a) on-table result and (b) postoperative day 29.

The ensuing history of silicone injection has followed a cyclical course of legitimization through quality control of product and administration, disappointingly poor new outcomes, further restriction of indications, and qualified successes causing renewed expressions of concern in the

medical community [3, 5, 6]. Silicone injection is currently only approved by the FDA for intra-ocular injection to treat retinal detachment, and not for injection anywhere in soft tissues [7, 8]. However, because of its status as a “device,” the material is allowed off-label use in a manner similar to botulinum toxin.

Proponents advocate the use of sterile, medical-grade material in a microdroplet technique [5, 9, 10]. Less than 0.1 ml is injected at a time, promoting soft tissue fibrosis that encapsulates and immobilizes the material. Still, material can migrate or lead to nodules, granuloma or infection [5]. Silicone gels typically generate a minimal host response, and as such are typically encapsulated by only a thin layer of fibroblasts. The lack of a thick, fibrous capsule can lead to migration of silicone droplets through tissues in a gravity-dependent manner. Foreign body reaction is common, but true granulomas are relatively rare. Silicone is notably the least likely of all permanent injectable filler materials to induce granuloma formation [11].

Silicones are readily detected in tissues as characteristically small, round to irregularly shaped translucent droplets of refractile and non-polarizing amorphous material. Identification via conventional light microscopy can be aided by cutting thicker tissue sections (10-30  $\mu\text{m}$ ) to prevent the loss of silicone droplets during routine tissue processing. Other modalities such as non-Koehler, phase contrast, and darkfield microscopy can be used to aid in visualization [12].

Unlike temporary fillers, injected silicone may require extensive procedures to treat or remove. Local and regional complications of varying degrees of severity have been treated with doxycycline, liposuction followed by fat grafting, debridement, mastectomy, and even hip replacement [13-17]. Most of these complications were delayed by years or decades after injection, and most did not migrate to distant areas such as the lower legs or feet. Rarer, potentially more serious complications include acute respiratory distress syndrome, massive silicone embolism and breast cancer [18-20].

Many of the above complications occurred in male-to-female transgender patients. Cross-sectional surveys have identified transgender women as especially vulnerable to predatory practices of body modification at cut rate prices. A response-driven sampling of 233 trans women in San Francisco recently identified a 16.7% weighted prevalence of non-medical silicone filler use [21]. Past and planned gender-confirming surgery were both associated with higher rates of silicone injection. Higher rates have also been reported among specific trans populations: 20% of 40 transgender sex workers surveyed in the Netherlands in 1999, and 29% of trans youth of color surveyed in Chicago in 2006 [22, 23].

The Charles procedure was first described in 1950 by Sir Archibald McIndoe, who incorrectly attributed it to Sir Richard Henry Havelock Charles (who had actually described treatment of scrotal lymphedema) [24]. The original procedure described by McIndoe uses split thickness skin graft obtained from the dermo fasciectomy resection specimen. In this case the resected skin was equally infiltrated with silicone, requiring the use of unaffected skin graft from the back. While appearing radical at first glance, a modified Charles procedure of the lower leg likely spared our patient an amputation.

## Conclusions

Injection of industrial-grade liquid silicone is an unfortunately common cosmetic procedure whose victims may lack the financial resources for safer surgical methods of feminization. These injections have the potential to cause inflammation and severe fibrosis well away from the zone of injection, even in the absence of frank tissue loss. Minor trauma or infection may develop into devastating complications.

While more commonly reported outside the United States, unsafe silicone injection is prevalent among male-to-female transgender women, especially those who have undergone surgical procedures for gender reassignment. As gender confirmation surgery becomes more widely performed, medical professionals serving the transgender community must take an active role in educating their patients against the dangers of unlicensed racketeers offering large-volume, industrial-grade silicone injection.

In the face of complications, it is important to recognize this clinical entity early so that appropriately aggressive therapy can be instituted. In the face of widespread infectious and inflammatory complications of silicone injection, aggressive dermo fasciectomy with skin grafting should be considered early as a limb salvage option.

## Acknowledgements

The authors have no conflicts of interest to report.

## Funding

The authors have no funding.

## REFERENCES

1. Braley S (1963) USE OF SILICONES IN PLASTIC SURGERY. *Arch Otolaryngol* 78: 669-675.
2. Kagan HD (1963) SAKURAI INJECTABLE SILICONE FORMULA. PRELIMINARY REPORT. *Arch Otolaryngol* 78: 663-668. [[Crossref](#)]
3. Webb MS (1997) Cleopatra's Needle: the history and legacy of silicone injections. Harvard Law School Student Papers.
4. Winer LH, Sternberg TH, Lehman R, et al. (1964) TISSUE REACTIONS TO INJECTED SILICONE LIQUIDS. A REPORT OF THREE CASES. *Arch Dermatol* 90: 588-5893. [[Crossref](#)]
5. Narins RS, Beer K (2006) Liquid injectable silicone: a review of its history, immunology, technical considerations, complications, and potential. *Plast Reconstr Surg* 118: 77S-84S. [[Crossref](#)]
6. Duffy DM (2002) The silicone conundrum: a battle of anecdotes. *Dermatol Surg* 28: 590-594.
7. FDA U (2017) Soft Tissue Fillers (Dermal Fillers).
8. Alpert S (1997) Premarket approval of Richard-James, Inc.'s SILIKON 1000 (purified polydimethylsiloxane) - ACTION.
9. Jacinto SS (2005) Ten-year experience using injectable silicone oil for soft tissue augmentation in the Philippines. *Dermatol Surg* 31: 1550-1554. [[Crossref](#)]
10. Benedetto AV, Lewis AT (2003) Injecting 1000 centistoke liquid silicone with ease and precision. *Dermatol Surg* 29: 211-214. [[Crossref](#)]
11. Lemperle G, Morhenn V, Charrier U (2003) Human histology and persistence of various injectable filler substances for soft tissue augmentation. *Aesthetic Plast Surg* 27: 354-366.



12. van Diest PJ, Beekman WH, Hage JJ (1998) Pathology of silicone leakage from breast implants. *J Clin Pathol* 51: 493-497. [[Crossref](#)]
13. Paul S, Goyal A, Duncan LM, Smith GP (2015) Granulomatous reaction to liquid injectable silicone for gluteal enhancement: review of management options and success of doxycycline. *Dermatol Ther* 28: 98-101. [[Crossref](#)]
14. Salgado CJ, Sinha VR, Desai U (2014) Liposuction and lipofilling for treatment of symptomatic silicone toxicosis of the gluteal region. *Aesthet Surg J* 34: 571-577. [[Crossref](#)]
15. Hage JJ, Kanhai RC, Oen AL, van Diest PJ, Karim RB (2001) The devastating outcome of massive subcutaneous injection of highly viscous fluids in male-to-female transsexuals. *Plast Reconstr Surg* 107: 734-741. [[Crossref](#)]
16. Mello DF, Gonçalves KC, Fraga MF, Perin LF, Helene A Jr (2013) Local complications after industrial liquid silicone injection: case series. *Rev Col Bras Cir* 40: 37-42. [[Crossref](#)]
17. Seeger JB, Ahmed GA, Basad E, Rickert M, Ishaque BA (2014) Gluteal silicone injections and total hip arthroplasty: a case report. *J Med Case Rep* 8: 140. [[Crossref](#)]
18. Coulaud JM, Labrousse J, Carli P, Galliot M, Vilde F, et al. (1983) Adult respiratory distress syndrome and silicone injection. *Toxicol Eur Res* 5: 171-174. [[Crossref](#)]
19. Price EA, Schueler H, Perper JA (2006) Massive systemic silicone embolism: a case report and review of literature. *Am J Forensic Med Pathol* 27: 97-102. [[Crossref](#)]
20. Nakahori R, Takahashi R, Akashi M, Tsutsui K, Harada S, et al. (2015) Breast carcinoma originating from a silicone granuloma: a case report. *World J Surg Oncol* 13: 72. [[Crossref](#)]
21. Wilson E, Rapues J, Jin H, Raymond HF (2014) The use and correlates of illicit silicone or "fillers" in a population-based sample of transwomen, San Francisco, 2013. *J Sex Med* 11: 1717-1724. [[Crossref](#)]
22. Wiessing LG, van Roosmalen MS, Koedijk P, Bieleman B, Houweling H (1999) Silicones, hormones and HIV in transgender street prostitutes. *AIDS* 13: 2315-2316. [[Crossref](#)]
23. Garofalo R, Deleon J, Osmer E, Doll M, Harper GW (2006) Overlooked, misunderstood and at-risk: exploring the lives and HIV risk of ethnic minority male-to-female transgender youth. *J Adolesc Health* 38: 230-236. [[Crossref](#)]
24. Dumanian GA, Futrell JW (1996) The Charles procedure: misquoted and misunderstood since 1950. *Plast Reconstr Surg* 98: 1258-1263. [[Crossref](#)]