Available online at www.sciencerepository.org

Science Repository

Research Article

# Evaluation of Socket Preservation Using Collagen Plug and Injectable Platelet Rich Fibrin in Extracted Sockets of Mandibular Molars: A Split Mouth Study

***K. Ganesh Sai Sandeep Kumar[1*], L. Krishna Prasad[2], P. Srinivas Chakravarthi[3], P. Raja Satish[3], Anand Vijay S[3], Vidya Sagar B[4] and K. S. Deekshith[1]***

[1]*Post Graduate, Department Of Oral And Maxillofacial Surgery, Sibar Institute Of Dental Sciences, Guntur, Andhra Pradesh, India*
[2]*Head of The Department, Department Of Oral And Maxillofacial Surgery, Sibar Institute Of Dental Sciences, Guntur, Andhra Pradesh, India*
[3]*Professor, Department Of Oral And Maxillofacial Surgery, Sibar Institute Of Dental Sciences, Guntur, Andhra Pradesh, India*
[4]*Senior Lecturer, Department Of Oral And Maxillofacial Surgery, Sibar Institute Of Dental Sciences, Guntur, Andhra Pradesh, India*

A R T I C L E  I N F O

*Article history:*
Received: 29 August, 2023
Accepted: 19 September, 2023
Published: 19 October, 2023

Keywords:
*Biocompatible materials*
*collagen*
*guided tissue regeneration*
*socket bone healing*

A B S T R A C T

**Aim and Objectives:** Evaluation of socket preservation using collagen plug and injectable platelet rich fibrin in extracted sockets of mandibular molars. To evaluate wound healing and bone density using collagen plug and I-PRF and to compare wound healing and bone density between collagen plug and I-PRF.

**Methodology:** This experimental study involves 13 healthy patients at the Sibar Institute of Dental Sciences and Hospital in Guntur, Andhra Pradesh, India, who underwent mandibular molar extraction under local anesthesia. Patients underwent clinical and radio-graphic examinations and received periodontal treatment. The study involved extraction of right and left mandibular molar teeth, AbGel placement, collagen plug placement, and sockets secured with sutures and pressure packs. Postoperative pain, swelling, and wound healing were assessed using Wong-Baker faces pain rating scale, VAS scale, and LANDRY healing index. CBCT was obtained after 1 month and 3 months after extraction for bone quality assessment.

**Results:** In the study, there were 69.2% men and 30.8% women. According to the study, 14.3% of individuals in the collagen plug group and 85.7% of those who received injectable platelet-rich fibrin experienced very good wound healing. On the first and seventh days, the mean pain intensity was lower in the injectable group, but there was not a noticeable distinction between the groups. The injectable group had the lowest swelling score, but by day seven, it had dramatically decreased. At the third month, the collagen plug group had the highest bone density readings, with no discernible difference between the groups.

**Conclusion:** It can be concluded that I-PRF can be utilized as an alternative to collagen plug.



## Introduction

When a tooth is deemed to be irrestorable, clinically, surgical extraction may be indicated. Edentulous sites can have a negatively affect patient quality of life and cause substantial anatomical changes to the alveolar ridge after the tooth is removed [1, 2]. It is proven fact that every tooth extraction leads to compromised alveolar bone [3]. Alveolar ridge resorption is a chronic, irreversible circumstance that caused a reduction in width varying from 2.6 to 4.6 mm and height ranging from 0.4 to 3.9 mm postextraction [4-6]. The majority of the alveolar bone resorption method varies within the first 3 to 6 months after extraction, however this practice is chronic, and the alveolar bone continues to resorb 25 years after the extractions [7]. Resorption rate varies from person to person and even from period to period for the same person. The resorption process differs between bones of maxilla and mandible noticeably, with the sockets of mandible which resorbs up to four times quicker than the socket of maxilla [5, 7].

In order to provide a platform for osteoblastic activity, induce bone formation at the site, and preserve the appropriate height of the alveolar ridge for future implant insertion, the grafting material should ideally be biocompatible and osteoconductive [8]. Materials for alveolar ridge

*Correspondence to: K. Ganesh Sai Sandeep Kumar, Post Graduate, Department Of Oral And Maxillofacial Surgery, Sibar Institute Of Dental Sciences, Guntur, Andhra Pradesh, India;*


http://dx.doi.org/10.31487/j.DOBCR.2023.02.01

preservation such as hydroxyapatite, beta-tricalcium phosphate, polylactide sponge, and Bio-Oss produce a variety of results. However, no substance has been found to be continually discovered benificial alveolar bone conservation [9-11]. Studies of intraalveolar treatment with different materials have shown that the placement of appropriate materials is more beneficial than the natural unloading of the alveoli [12, 13].

Filling the post-extraction socket with type-1 collagens helps to prevent complications by forming new granulation tissue, stabilizing blood clots, and protecting the wound. In the extraction sockets, blood clots provides scaffolds for new blood vessel and promote wound healing. The commonest filling material that can be utilised to control alveolar bone retention is the collagen plug. The pure type-1 collagen plug facilitates healing process in socket by maintaining the blood clot in the extraction socket, generating new granulation tissue and enough porosity for post-operative blood penetration. To conclude the technique of injecting pure type 1 collagen placed in post extraction socket has gained popularity over time [14].

In both dental and medical fields, there is always an innovative path for invention of advanced techniques based on different procedures and it is a never-ending process. Studies showed the impact of blood cells on biomaterials used in the human body have been conducted. This evolution began in the late 1990s with the centrifugation of platelet-rich plasma (PRP), and was followed by next generation of platelet aggregates, platelet-rich fibrin (PRF), till the latest advanced platelet-rich fibrin clot (a-PRF) [15, 16]. Platelet aggregates in injectable form are now widely used to achieve favorable results. Injectable PRF (i-PRF) is a latest PRF matrix obtained from venous blood by low centrifugation forces and shorter centrifugation times. Injectable PRF (i-PRF) contains a variety of growth factors and inflammatory cells that are important for tissue regeneration [17]. It has been used to treat extraction sockets, gingival recessions, palate wound closure, periodontal defect regeneration, and hyperplastic gingival tissues. Better wound healing, enhanced angiogenesis, lower cost effective, and perfect immune-biocompatibility are all advantages of injectable PRF [18,19]. However i-PRF can be utilized as adjuvant regenerative material with structural variations as particles or as a block graft material, which is not often indicated in regenerative dentistry, yet. With this context the respective study conducted to evaluate the socket preservation placing collagen plug and injectable platelet rich fibrin in extracted sockets of mandibular molars.

## Methodology

This study was designed as experimental study undertaken in the Department of Oral and Maxillofacial Surgery, Sibar Institute Of Dental Sciences and Hospital, Guntur between the period of February 2021-September 2022, after approval of the Institutional Ethics Committee (ECR/1362/Inst/AP/2020).

### I Study Population

Thirteen healthy patients who attended to the Department of Oral and Maxillofacial Surgery, Sibar Institute Of Dental Sciences and Hospital, Guntur without deviations from normal vital signs, measured in the preoperative period who required mandibular molar extraction under local anesthesia and who were willing to participate and sign an informed consent form, were selected for the study. Pregnant and lactating women and expected cases of traumatic extraction were not included in the study. Prior to the study, all patients underwent clinical and radio-graphic examination and received periodontal treatment as needed.

### II Study Procedure

Participants were selected based on inclusion and exclusion criteria. Right and left mandibular molar teeth were extracted using 2% lignocaine hydrochloride containing 1:80000 adrenaline. With an interval of one week. AbGel was placed in the right molar socket, soaking in I-PRF. Collagen Plug was placed on the left side, and sockets secured with figure of eight sutures and a pressure pack. Patients were recalled on 1st and 7th postoperative days for the assessment of pain and swelling using Wong-Baker faces pain rating scale and VAS scale, while wound healing was assessed using LANDRY healing index [20-22]. CBCT was obtained after 1 month and 3 months after extraction for assessment of bone quality.

### III I-PRF Preparation

Scrub the area with iodine at the site of penetration of needle and 10ml venous blood of the patient had taken and centrifuged at the speed of 700 rpm for 180 seconds. This low speed centrifugation had divided I-PRF and RBC. On the top of the test tube I-PRF seen and carefully I-PRF is collected from the tube with a syringe and placed in the extraction socket by soaking in AbGel and figure of eight sutures will be placed (Figures 1-6).

**Figure 1:** Blood collection FOR i-PRF.

**Figure 2:** Centrifugation.

**Figure 3:** Collecting I-PRF.



**Figure 4:** ABGEL soaked in i-PRF.

### IV Statistical Analysis

Data was compiled using Microsoft excel software and analyzed using statistical package for social science (SPSS Version 25). Descriptive statistics were used to summarize the results. Kolmogorov Smirnov tests revealed that the study data were non-normally distributed, and hence non-parametric tests were employed to compare the study parameters between both the groups and tests used were Man-Whitney U test and Friedman test.

### Results

The mean age of the male subjects was 23.11±4.8 years. The mean age of the female participants was 25.25±3.2 years. Overall mean age of the participants was 23.7±4.36 years. Among the study subjects 30.8% of the participants were females where as 69.2% of them were males (Table 1). Table 2 depicts the comparison of wound healing on 7$^{th}$ day follow-up between both the groups.85.7% of the subjects in injectable platelet rich fibrin group achieved very good wound healing where as in collage plug group only 14.3% achieved very good wound healing and the difference observed between both the groups was statistically significant (P=0.037). The mean pain intensity was lower in the injectable platelet rich fibrin group on 1$^{st}$ day and 7$^{th}$ day when compared with collagen plug group and there was no statistically significant difference observed between both the groups ((P=0.245) and (P=0.095)),while comparison of intensity of pain in injectable platelet rich fibrin group and also in collagen plug group at different time intervals revealed a statistically significant difference between 1$^{st}$ day and 7$^{th}$ day follow-up (P=0.001 and 0.008) (Table 3).

**Table 1:** Descriptive statistics regarding age and gender of the study subjects.

| | **Age** | | **Gender** | |
|---|---|---|---|---|
| | Males | Females | Males | Females |
| **Descriptives of the study subjects** | 23.11±4.8 | 25.25±3.2 | 69.2% | 30.8% |
| **Overall mean age** | 23.7±4.36 | | | |

**Table 2:** Comparison of wound healing between two groups.

| Group | good | Very good |
|---|---|---|
| Injectable platelet rich fibrin | 36.8% | 85.7% |
| Collagen plug | 63.2% | 14.3% |
| P value | 0.037* | |

Chi-square test p≤0.05 was considered statistically significant.

*denotes statistically significant.

**Table 3:** Comparison of intensity of pain at 1$^{st}$ and 7$^{th}$ day between both the groups.

| Follow-up | **Injectable platelet rich fibrin** | **Collagen plug** | Z score | P-value |
|---|---|---|---|---|
| 1$^{st}$ day | 11.92 | 15.08 | -1.163 | 0.245 |
| 7$^{th}$ day | 11.27 | 15.73 | -1.670 | 0.095 |
| Sum of Ranks | 91.00 | 61.50 | - | - |
| P-value | 0.001* | 0.008* | - | - |

Man-Whitney U test; Wilcoxon sign rank test ;p≤0.05 was considered statistically significant.

Table 4 depicts the comparison of swelling at 1st and 7th day between both the groups. The mean swelling score was lowest for injectable platelet rich fibrin group when compared with collagen plug group and the difference was not statistically significant (P=0.23). On 7th day follow-up an decrease in swelling observed in both the groups and the difference observed was statistically significant (P=0.006). A significantly reduced swelling was observed from 1st day to 7th day follow-up in both the groups (P=0.001). Highest bone density values were observed for collagen plug group on 3rd month follow-up (717.23). There was no statistically significant difference seen between injectable platelet rich fibrin group and collagen plug group on both 1st month and 3rd month follow-up (P≥0.05). Comparison of bone density at different time intervals reveals a significant increase in bone density from 1st month to 3rd month follow-up (P=0.001) in both the groups (Table 5). Changes in bone density was observed in the extraction site from 1st month to 3rd month follow-up after placement of iprf and collagen (Figures 7-10).

**Table 4:** Comparison of swelling scores of two groups at 1st and 7th day between two groups.

| Follow-up | **Injectable platelet rich fibrin** | **Collagen plug** | Z score | P-value |
|---|---|---|---|---|
| 1st day | 11.96 | 15.04 | -1.180 | 0.238 |
| 7th day | 9.62 | 17.38 | -2.766 | 0.006* |
| Sum of Ranks | 91.00 | 78.00 | - | - |
| P-value | 0.001* | 0.001* | - | - |

Man-Whitney U test; Wilcoxon sign rank test ;p≤0.05 was considered statistically significant.

**Table 5:** Comparison of bone density scores at 1st month and 3rd month between two groups.

| Follow-up | **Injectable platelet rich fibrin** | **Collagen plug** | Z score | P-value |
|---|---|---|---|---|
| 1st month | 11.00 | 16.00 | -1.667 | 0.096 |
| 3rd month | 11.62 | 15.38 | -1.256 | 0.209 |
| Sum of Ranks | 78.00 | 91.00 | - | - |
| P-value | 0.001* | 0.001* | - | - |

Man-Whitney U test; Wilcoxon sign rank test ;p≤0.05 was considered statistically significant.

**Figure 5:** Collagen plug.


**Figure 6:** ABGEL.

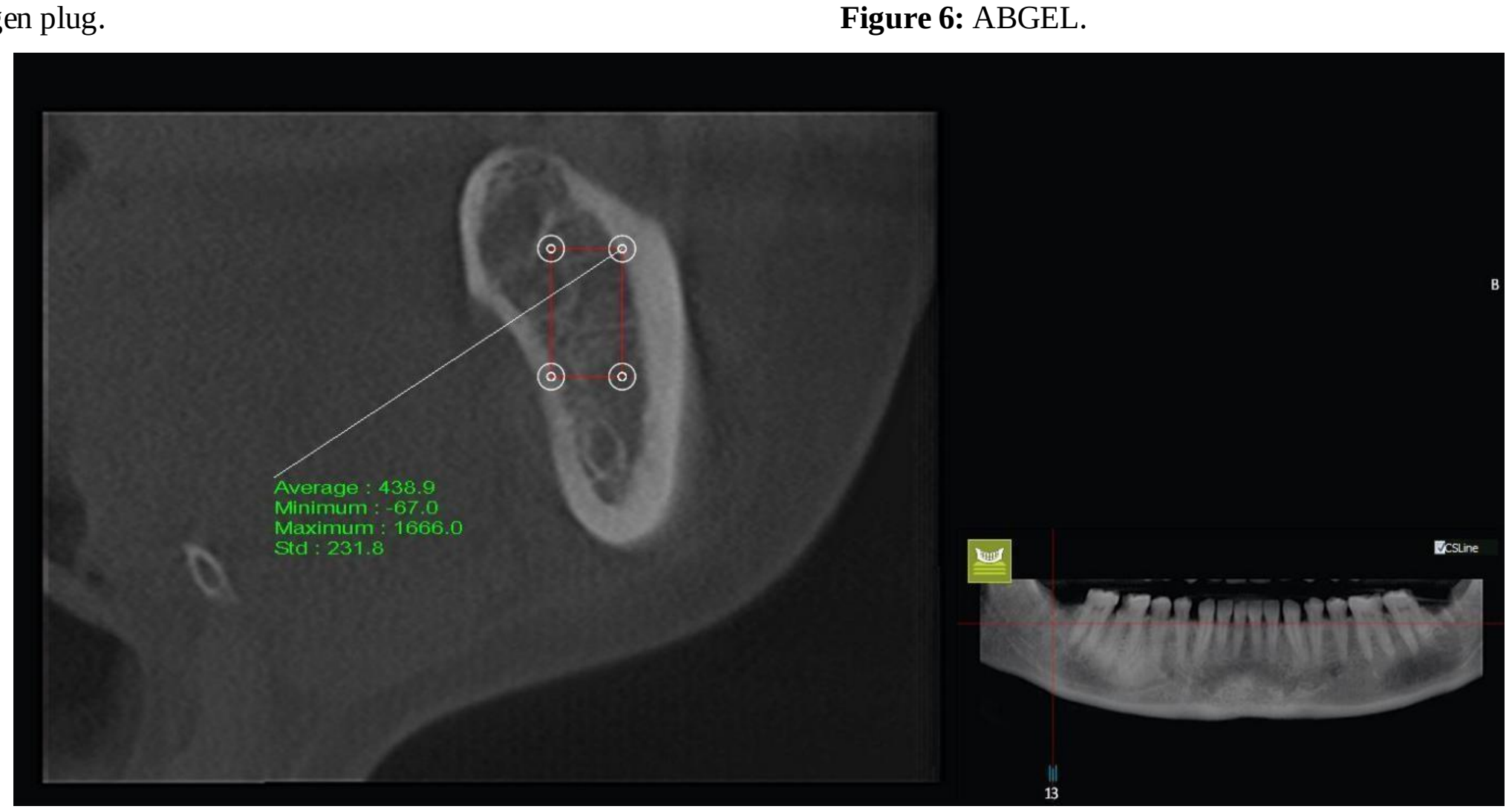


**Figure 7:** Bone density of 48 region after 1M.

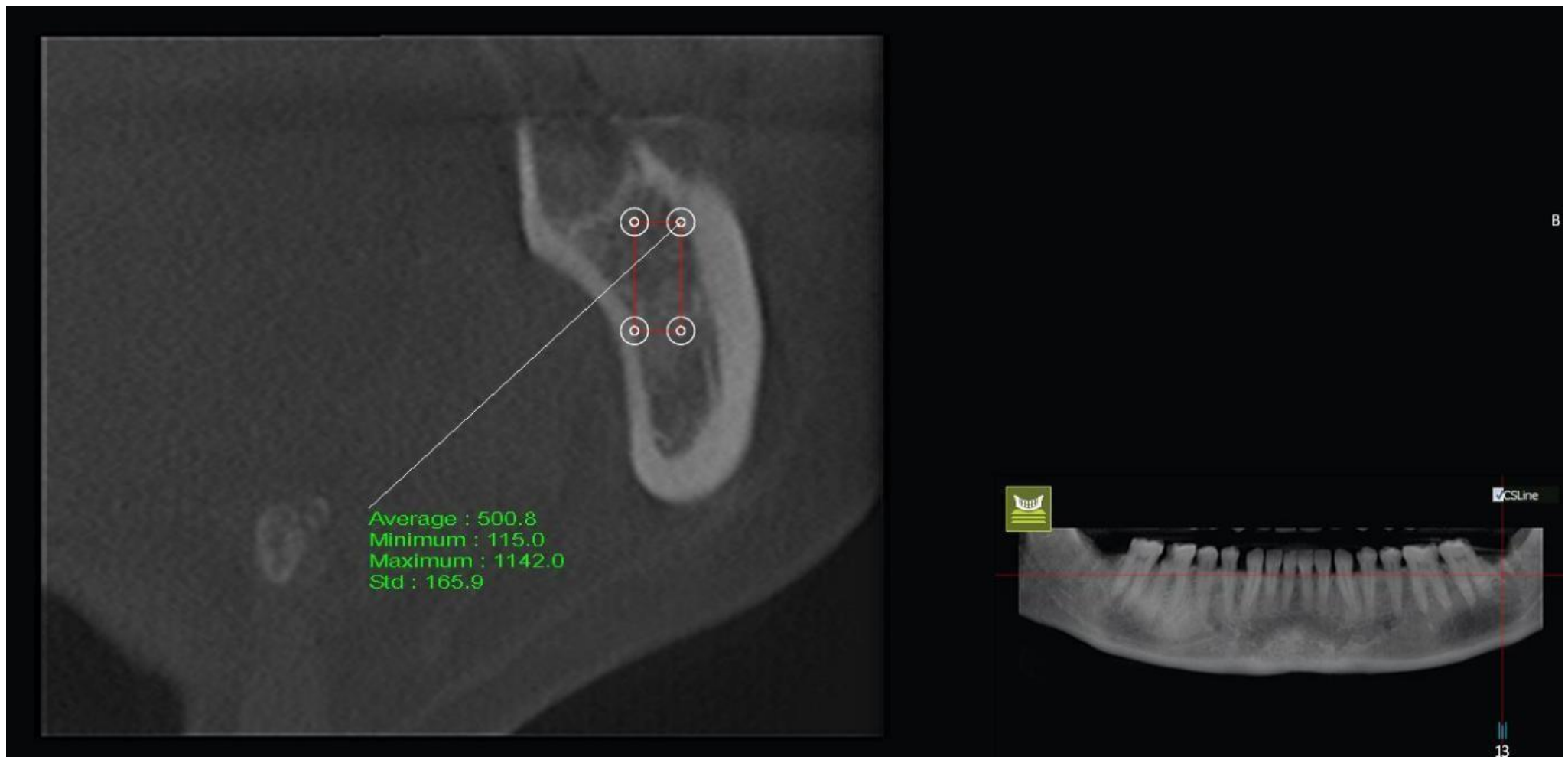


**Figure 8:** Bone density of 38 region after 1M.


**Figure 9:** Bone density of 38 region after 3M.


**Figure 10:** Bone density of 48 region after 3M.

## Discussion

Teeth are crucial for bone health and are often extracted for various reasons, including root fractures, periapical pathologies, periodontal disease, and extensive decay. Tooth extraction leads to disuse atrophy of surrounding alveolar bone, causing shrinkage and receding gums. Alveolar bone loss can result from facial trauma, endodontic pathology, periodontitis, and extraction techniques. To minimize bone loss, socket preservation is introduced, using a synthetic biomaterial to stabilize blood clots, prevent tissue reduction, and provide a scaffold for cellular and vascular growth [23, 24]. Socket preservation materials include autograft, allograft, and xenograft. Autograft Bone promotes new bone formation, while allograft bone comes from different species. Xenograft is biologically derived from animals, corals, or algae [23]. Collagen, a major component of connective tissue, provides structural aid and stimulates platelet adhesion. Type-1 collagen is used for post-extraction socket preservation, reducing complications and protecting the wound. A novel technique for socket preservation is the use of a collagen plug, a cylindrically shaped sponge that stabilizes blood clots, insulates bone, and helps in hemostasis at the extraction site. Collagen plugs are used for soft tissue healing and hard tissue reconstruction [25, 26].

PRP, introduced two decades ago, is a concentrated source of growth factors used in tissue engineering and wound healing. It provides a scaffold for periosteal cells *in vitro*, promoting osteogenesis, osteoinduction, and osteoconduction. Gelfoam packing is not effective in fibroblast growth or mitosis. G-graft, made from natural low crystalline hydroxyapatite, serves as a scaffold for growing cells and strengthens clots. It is porous and can be re-sterilized. Regenerative dentistry has become the standard of care, with PRF prepared from patient's blood for faster bone regeneration and better healing. I-PRF was developed to address this issue by incorporating liquid protein concentrate, anticoagulants, and fibrin matrix [27, 28].

Ghanaati *et al.* developed a low-speed concept for blood centrifugation, revealing that lower centrifugation speeds increased cell count, including leukocytes, before fibrin clot formation [29]. This led to the development of i-PRF, a new platelet aggregate alternative in medicine and dentistry. It is autogenous, reduces adverse reactions, and can bond with biomaterials for bone grafting. Liquid PRF is cost-effective and comparable to bovine-derived fibrin. I-PRF is used in dermatology, cosmetology, implant dentistry, but studies on its effectiveness for socket preservation are limited [30, 31]. In this context, the current study has been carried out with the objective of assessing socket preservation using collagen plugs and injectable platelet rich fibrin in extracted mandibular molar sockets. The present study includes 13 patients who underwent bilateral mandibular molar extractions, with I-PRF soaked in gel placed in the extraction socket on the right side and collagen plug placed on the left side. A 1-week gap was maintained between surgeries. Results showed no significant difference in pain, swelling, wound healing, or bone density between I-PRF and collagen plug.

### I Pain

The pain intensity in the injectable platelet rich fibrin group was lower on the 7$^{th}$ day compared to the collagen plug group. This finding is similar to previous studies involving socket filling with collagen plugs. A study done by Vincent saliba *et al.* where socket filling was done with collagen plug and Bio-oss concluded that Bio-Oss experienced more pain in the seven days following surgery [32]. Another study done by Shang-Jye Tsai *et al.* concluded that patients with collagen (type-1) insertion into the post extraction socket had markedly decreased pain than the control group, and also had notably reduced post-operative pain time scale than the control group, where the findings were similar to the current study [14]. S A Puia *et al.* found that textured collagen (MC) in porcine or bovine can reduce postoperative pain and improve wound healing [33]. According to Norman Shaw *et al.*, study, all 25 participants in the collagen group showed remarkably low levels of pain [34]. Zhang *et al.* found that i-PRF affects immune cell responses, suppressing macrophage M1 polarization and DC maturation [35].

### II Swelling

On comparing the mean swelling scores between I-PRF and collagen plug on 1$^{st}$ and 7$^{th}$ day I-PRF has the lower score on both the 1$^{st}$ and 7$^{th}$ day. There was no statistically significant swelling score between both the groups on 1$^{st}$ day whereas on seventh day I-PRF has the lowest swelling score and is statistically significant when compared with collagen plug. There is statistically significant difference in swelling in both I-PRF and collagen group from 1$^{st}$ day to 7$^{th}$ day. A study done by Hoon Cho, *et al.* described that collagen plugs (Type-I) are used to fill extraction wounds in order to optimize hemostasis, promote granulation tissue formation, and protect the wound surface [36]. Collagen sponges help to reduce swelling and pain after surgery. The use of collagen plugs in third molar extractions was associated with a low level of complication rates in their study. Swelling was completely reduced in eight patients on the collagen plug placed side, according to a study conducted by Murugan Ranganathan *et al.* [37]. Six patients had moderate swelling on the first postoperative day, three had mild swelling, and one patient had no visible swelling. The findings were not in accordance with the present study.

### III Wound Healing

On comparison of wound healing on 7$^{th}$ day follow-up between both the groups the I-prf group had very good wound healing of 85.7% compared to only 14.3% in collagen plug group showing statistically significant difference between both the groups in wound healing on 7$^{th}$ day. Liquid PRF, consisting of autologous growth factors like PDGF, TGF-β1, and VEGF, assists in wound healing by assisting platelets and leukocytes in repairing damaged tissue. It helps in process of wound healing as it contains a number of autologous growth factors found in blood, such as platelet-derived growth factors (PDGF), transforming growth factor-beta (TGF-1) and vascular endothelial growth factor (VEGF), as well as cells (platelets and leukocytes) [38]. A study conducted by Shang-Jye Tsai *et al.* concluded that patients who received type-1 collagen placement into the extraction socket had significantly better wound healing and less probing depth than the control group which is not in accordance with the present study [14]. Vincent Saliba *et al.* in their study concluded that sockets which are filled with collagen plug has healing of upto 60% compared to bioss graft [32]. Numaan Nisar *et al.*, found no significant difference in wound healing after extraction socket grafting with collagen plug and no graft material. Singh *et al.*, found that sockets grafted with hydroxyapetite with collagen had less probing depth and better wound healing [39, 40]. Athanasios *et al.* found FDBA/βTCP and rhPDGF-BB improve wound healing compared to collagen alone, while

Ahmad Kutkut *et al.* found MGCSH mixed with PRP improves wound healing in 10 days [41, 42].

**IV Bone Density**

The bone density in iprf group increased from 1st month to third month in both IPRF and collagen group but highest bone density was found in collagen plug group on 3rd month follow up. Jeong-Kui Ku *et al.* conducted a study in which socket grafting was done using DBM/rhBMP-2 and collagen and DBM/rhBMP-2 showed better bone healing than collagen [43]. In the present study there was no statistically significant difference between I-prf group and collagen plug group on both 1st and 3rd month follow up in terms of bone density but highest bone density was observed during 3rd month follow-up of collagen plug group.

Lydia N. Melek, *et.al.*, compared GBR and I-PRF before implant placement to prevent bone resorption and enhance alveolar ridge dimensions [30]. She suggested injectable PRF with high growth factor composition for predictable bone formation. Kotskis *et al.* found that extraction sockets preserved with organic bone material had 14% resorption after 3 months. Athanasios *et al.* found that collagen plug, FDBA/βTCP+ collagen, FDBA/β TCP+collagen+PRP, and FDBA/β TCP+collagen+rhPDGF-BB had better healing capacity and eliminated D2 type bone formation [41]. Studies have shown that MGSCH mixed with PRP and collagen plug can increase vital bone volume at 3m. Biooss+Iprf can regenerate wide infrabony defects. I-PRF and A-PRF augmentation of ridges and sinus floor augmentation have better bone formation. DBBM+I-PRF has been found to be more effective in sinus floor augmentation [44, 45].

PRP increased osteoblast migration by a double-fold, while i-PRF induced a three-fold increase. i-PRF accelerated ALP staining and alizarin red staining, and increased mRNA levels of ALP, Runx2, and osteocalcin. It is used in facial skin regeneration and tissue regeneration. Leukocytes play an important role in tissue regeneration functions, which include stimulus of fibroblast propagation, enhance anti-inflammatory effects, angiogenesis, and protein deposition, via a cluster of mesenchymal stem cells.

## Conclusion

The results showed that although collagen plugs had the highest bone density values at the third month of follow-up, there was no statistically significant difference between injectable platelet rich fibrin and collagen plug in terms of pain, swelling, or wound healing. So, it can be concluded that I-PRF can be utilized as an alternative to collagen plug.

## References


1. Schropp L, Wenzel A, Kostopoulos L, Karring T (2003) Bone healing and soft tissue contour changes following single-tooth extraction: a clinical and radiographic 12-month prospective study. *Int J Periodontics Restorative Dent* 23: 313-323. [Crossref]
2. Cardaropoli D, Cardaropoli G (2008) Preservation of the postextraction alveolar ridge: a clinical and histologic study. *Int J Periodontics Restorative Dent* 28: 469-477. [Crossref]
3. Atwood DA (1971) Reduction of residual ridges: a major oral disease entity. *J Prosthet Dent* 26: 266-279. [Crossref]
4. Cawood JI, Howell R (1988) A classification of the edentulous jaws. *Int J Oral Maxillofac Surg* 17: 232-236. [Crossref]
5. Atwood DA, Coy WA (1971) Clinical, cephalometric, and densitometric study of reduction of residual ridges. *J Prosthet Dent* 26: 280-295. [Crossref]
6. Ten Heggeler JM, Slot DE, Van der Weijden GA (2011) Effect of socket preservation therapies following tooth extraction in non-molar regions in humans: a systematic review. *Clin Oral Implants Res* 22: 779-788. [Crossref]
7. Tallgren A (1972) The continuing reduction of the residual alveolar ridges in complete denture wearers: a mixed-longitudinal study covering 25 years. *J Prosthet Dent* 27: 120-132. [Crossref]
8. Jones K, Williams C, Yuan T, Digeorge Foushee AM, Wilson RC et al. (2022) Comparative in vitro study of commercially available products for alveolar ridge preservation. *J Periodontol* 93: 403-411. [Crossref]
9. Araújo MG, Liljenberg B, Lindhe J (2010) β-tricalcium phosphate in the early phase of socket healing: an experimental study in the dog. *Clin Oral Implants Res* 21: 445-454. [Crossref]
10. Serino G, Biancu S, Iezzi G, Piattelli A (2003) Ridge preservation following tooth extraction using a polylactide and polyglycolide sponge as space filler: a clinical and histological study in humans. *Clin Oral Implants Res* 14: 651-658. [Crossref]
11. Carmagnola D, Adriaens P, Berglundh T (2003) Healing of human extraction sockets filled with Bio-Oss®. *Clin Oral Implants Res* 14: 137-143. [Crossref]
12. Becker W, Clokie C, Sennerby L, Urist MR, Becker BE (1998) Histologic findings after implantation and evaluation of different grafting materials and titanium micro screws into extraction sockets. *J Periodontol* 69: 414-421. [Crossref]
13. Heberer S, Al Chawaf B, Jablonski C, Nelson JJ, Lage H et al. (2011) Healing of ungrafted and grafted extraction sockets after 12 weeks: a prospective clinical study. *Int J Oral Maxillofac Implants* 26: 385-392. [Crossref]
14. Tsai SJ, Chen MH, Lin HY, Lin CP, Chang HH (2019) Pure type-1 collagen application to third molar extraction socket reduces postoperative pain score and duration and promotes socket bone healing. *J Formos Med Assoc* 118: 481-487. [Crossref]
15. Marx RE, Carlson ER, Eichstaedt RM, Schimmele SR, Strauss JE et al. (1998) Platelet-rich plasma: growth factor enhancement for bone grafts. *Oral Surg Oral Med Oral Pathol Oral Radiol Endod* 85: 638-646. [Crossref]
16. Choukroun J, Adda F, Schoeffler C, Vervelle AP (2001) Une opportunité en paroimplantologie:le PRF. *Implantodontie* 2: e62.
17. Shah R, Gowda TM, Thomas R, Kumar T, Mehta DS (2019) Biological activation of bone grafts using injectable platelet-rich fibrin. *J Prosthet Dent* 121: 391-393. [Crossref]
18. Sammartino G, Ehrenfest DM, Carile F, Tia M, Bucci P (2011) Prevention of hemorrhagic complications after dental extractions into open heart surgery patients under anticoagulant therapy: the use of leukocyte-and platelet-rich fibrin. *J Oral Implantol* 37: 681-690. [Crossref]
19. Hoaglin DR, Lines GK (2013) Prevention of localized osteitis in mandibular third molar sites using platelet-rich fibrin. *Int J Dent* 2013: 875380. [Crossref]
20. Wong-Baker FACES Pain Rating Scale.

21. Berge TI (1988) Visual analogue scale assessment of postoperative swelling. A study of clinical inflammatory variables subsequent to third-molar surgery. *Acta Odontol Scand* 46: 233-240. [Crossref]
22. Lingamaneni S, Mandadi LR, Pathakota KR (2019) Assessment of healing following low-level laser irradiation after gingivectomy operations using a novel soft tissue healing index: A randomized, double-blind, split-mouth clinical pilot study. *J Indian Soc Periodontol* 23: 53-57. [Crossref]
23. Dimova C (2014) Socket preservation procedure after tooth extraction. *InKey Engineering Materials* 587: 325-330.
24. Irinakis T (2006) Rationale for Socket Preservation after Extraction of a Single- Rooted Tooth when planning for Future Implant Placement. *J Can Dent Assoc* 72: 917-922. [Crossref]
25. Kotsakis G, Markou N, Chrepa V, Krompa V, Kotsakis A (2012) Alveolar ridge preservation utilizing the 'socket plug'technique. *Int J Oral Implantol Clin Res* 3: 24-30.
26. Kim YK, Yun PY, Lee HJ, Ahn JY, Kim SG (2011) Ridge preservation of the molar extraction socket using collagen sponge and xenogeneic bone grafts. *Implant Dent* 20: 267-272. [Crossref]
27. Coomes AM, Mealey BL, Huynh Ba G, Barboza Arguello C, Moore WS et al. (2014) Buccal bone formation after flapless extraction: a randomized, controlled clinical trial comparing recombinant human bone morphogenetic protein 2/absorbable collagen carrier and collagen sponge alone. *J Periodontol* 85: 525-535. [Crossref]
28. Feng L, Zhang L, Cui Y, Song TX, Qiu ZY et al. (2016) Clinical evaluations of mineralized collagen in the extraction sites preservation. *Regen Biomater* 3: 41-48. [Crossref]
29. Ghanaati S, Booms P, Orlowska A, Kubesch A, Lorenz J et al. (2014) Advanced platelet-rich fibrin: new concept for cell-based tissue engineering by means of inflammatory cells. *J Oral Implantol* 40: 679-689. [Crossref]
30. Melek LN, Taalab MR (2017) The Use of Injectable Platelet Rich Fibrin in Conjunction to Guided Bone Regeneration for the Management of Well Contained Ridge Defect at the Time of Extraction. *Egyptian Dental Journal* 63: 1197-1208.
31. Miron RJ, Fujioka Kobayashi M, Hernandez M, Kandalam U, Zhang Y et al. (2017) Injectable platelet rich fibrin (i-PRF): opportunities in regenerative dentistry? *Clin Oral Investig* 21: 2619-2627. [Crossref]
32. Saliba V, Nader N, Berberi A, Chamoun WT (2022) Collagen Versus Xenograft Bovine Bone Inserted Into Extraction Sockets: Healing and Pain Management. *J Maxillofac Oral Surg* 21: 1101-1111. [Crossref]
33. Puia SA, Hilber EM, Garcia Blanco M (2020) Randomized clinical trial comparing three local hemostatic agents for dental extractions in patients under chronic anticoagulant therapy-a comparative study. *Ann Maxillofac Surg* 10: 292-296. [Crossref]
34. Shaw N (1991) Textured collagen, a hemostatic agent: A pilot study. *Oral Surg Oral Med Oral Pathol* 72: 642-645. [Crossref]
35. Zhang J, Yin C, Zhao Q, Zhao Z, Wang J et al. (2020) Anti-inflammation effects of injectable platelet-rich fibrin via macrophages and dendritic cells. *J Biomed Mater Res A* 108: 61-68. [Crossref]
36. Cho H, Jung HD, Kim BJ, Kim CH, Jung YS (2015) Complication rates in patients using absorbable collagen sponges in third molar extraction sockets: a retrospective study. *J Korean Assoc Oral Maxillofac Surg* 2015 41: 26-29. [Crossref]
37. Ranganathan M, Balaji M, Krishnaraj R, Narayanan V, Thangavelu A (2017) Assessment of regeneration of bone in the extracted third molar sockets augmented using xenograft (CollaPlugTN Zimmer) in comparison with the normal healing on the contralateral side. *J Pharm Bioallied Sci* 9: S180-S186. [Crossref]
38. Miron RJ, Fujioka Kobayashi M, Hernandez M, Kandalam U, Zhang Y et al. (2017) Injectable platelet rich fibrin (i-PRF): opportunities in regenerative dentistry? *Clin Oral Investig* 21: 2619-2627. [Crossref]
39. Nisar N, Nilesh K, Parkar MI, Punde P (2020) Extraction socket preservation using a collagen plug combined with platelet-rich plasma (PRP): A comparative clinico-radiographic study. *J Dent Res Dent Clin Dent Prospects* 14: 139-145. [Crossref]
40. Singh M, Bhate K, Kulkarni D, Santhosh Kumar SN, Kathariya R (2015) The effect of alloplastic bone graft and absorbable gelatin sponge in prevention of periodontal defects on the distal aspect of mandibular second molars, after surgical removal of impacted mandibular third molar: a comparative prospective study. *J Maxillofac Oral Surg* 14: 101-106. [Crossref]
41. Ntounis A, Geurs N, Vassilopoulos P, Reddy M (2015) Clinical assessment of bone quality of human extraction sockets after conversion with growth factors. *Int J Oral Maxillofac Implants* 30: 196-201. [Crossref]
42. Kutkut A, Andreana S, Kim H II, Monaco Jr E (2012) Extraction socket preservation graft before implant placement with calcium sulfate hemihydrate and platelet-rich plasma: A clinical and histomorphometric study in humans. *J Periodontol* 83: 401-409. [Crossref]
43. Ku JK, Jeong YK (2021) Effectiveness of bone graft for an alveolar defect on adjacent second molar after impacted mandibular third molar extraction. *J Oral Maxillofac Surg* 79: 756-762. [Crossref]
44. Gulsen U, Dereci O (2019) Evaluation of New Bone Formation in Sinus Floor Augmentation With Injectable Platelet-Rich Fibrin-Soaked Collagen Plug: A Pilot Study. *Implant Dent* 28: 220-225. [Crossref]
45. Sharma MH, Kumar GS, Sharma M, Nair UP (2020) i-PRF a Boon In Regenerative Periodontal Therapy: A Case Report of 1-Year Follow-Up. *Saudi J Oral Dent Res* 5: 582-586.