

Available online at [www.sciencerepository.org](http://www.sciencerepository.org)

Science Repository



## Case Report

# ICD-Electrode-Perforation of the Right Ventricle to the Pericardium with and without Pericardial Effusion

Line Lisbeth Olesen\*

Department of Cardiology, Zealand University Hospital, Roskilde, Denmark

### ARTICLE INFO

#### Article history:

Received: 30 May, 2020

Accepted: 12 June, 2020

Published: 19 June, 2020

#### Keywords:

ICD-electrode

cardiac perforation

cardiac tamponade

loss of capture

echocardiography

gated CT

### ABSTRACT

Two cases are described of iatrogenic traumatic perforation of an ICD electrode through the myocardium in the right ventricle and to the pericardium. The diagnostic gold standard gated CT was not necessary in either case. In the first case the lead insertion was difficult, time-consuming, and complicated by the Post-Cardiac Injury Syndrome and a slowly accumulating hemorrhagic pericardial effusion causing cardiac tamponade, diagnosed by the clinical picture, elevated CRP, ECG with low voltage and electrical alternans, chest X-ray revealing enlarged cardiac silhouette and echocardiography a large effusion, treated with pericardiocentesis and drainage. In the other case there was painful pericardial irritation and extracardiac pacing and ICD failure with loss of capture, no diagnostic changes in ECG, chest X-ray, and echocardiography; diagnosed by fluoroscopy during replacement at the lead, which went without complications and without pericardial effusion.

© 2020 Line Lisbeth Olesen. Hosting by Science Repository.

### Introduction

About 1% of all pacemaker implantations are complicated by symptomatic perforation of the cardiac wall within one month after implantation. The perforation spans from insignificant with the cardiomyocytes contracting and closing the defect to perforation of the helix outside the heart injuring the pericardium, pleura, and organs. The symptoms span from discrete to lethal. Knowledge of this potentially fatal complication is important in order to diagnose and treat it in due time [1-6].

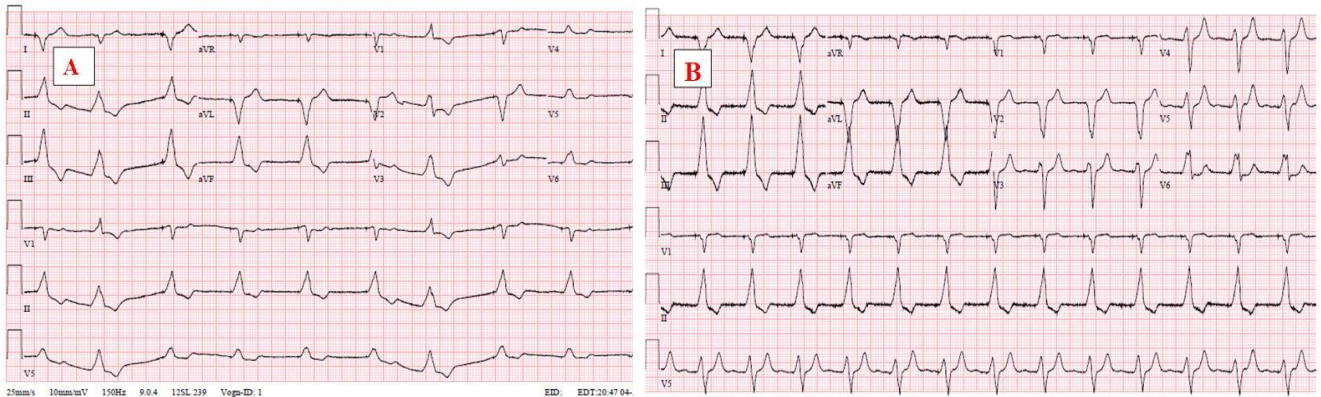
### Case-1

A 64-year-old male had a VVI-Pacemaker (PM) implanted due to slow atrial fibrillation and syncope. CRP was <2,9 mg/L and BMI was 30. Two weeks later, he was diagnosed with Arrhythmogenic Right Ventricular Cardiomyopathy (ARVC) and Ventricular Tachycardia (VT). He had the brady pacemaker explanted and a VVI-Implantable Cardioverter Defibrillator (ICD) implanted instead. Upon examination, the right cavities were found to be hugely dilated. On both occasions, the

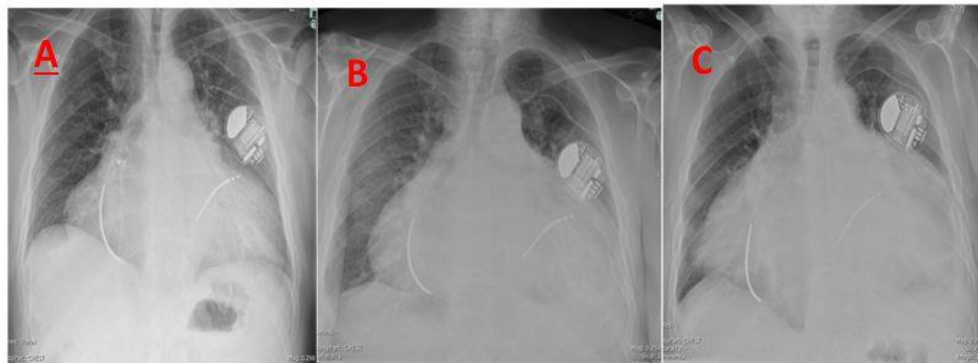
electrode was tested in several positions. The ICD electrode was finally secured on the septum with acceptable values which remained stable. He was discharged the following day.

Two weeks later, he started experiencing increasing dyspnea and growing edemas. CRP was elevated to 140 mg/L. Six weeks after the implantation procedure he was readmitted in a very poor state with severe respiratory difficulties, orthopnea, pulsus paradoxus, and anasarca corresponding to pericardial tamponade. CRP 30 mg/L. ECG (Figure 1), chest X-ray (Figure 2), and echocardiography (Figure 3) confirmed the diagnosis. Echocardiography revealed a large pericardial effusion measuring 4 cm around the swinging heart and compressing the cavities. Pericardiocentesis resulted in removal of three liters of sanguineous serous fluid. Afterwards the CRP was elevated to 100 mg/L for about a fortnight, when it started to fall and about a month after the pericardiocentesis CRP was <2,9 mg/L, where it has remained since. The ICD electrode was operating well. As the electrode was still located on the septum, it did not cause the pericardial perforation and for this reason, it was not replaced. A small pericardial effusion was seen for some weeks after the pericardiocentesis and then disappeared without any treatment and the patient recuperated.

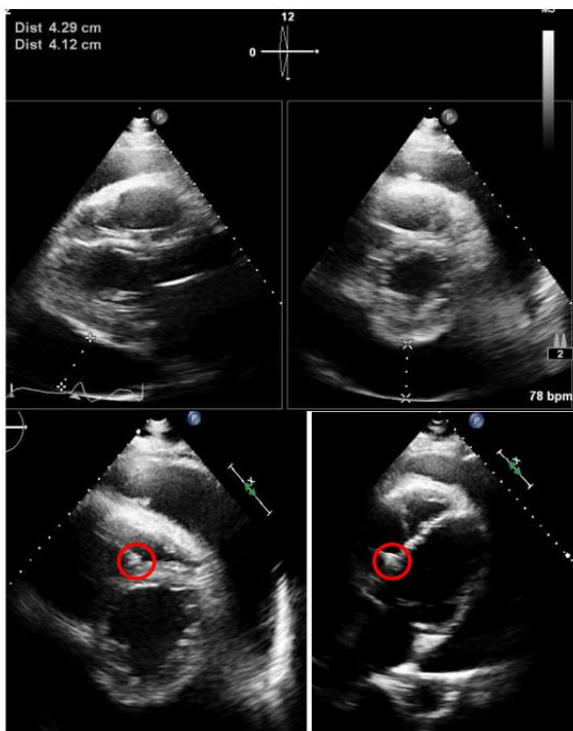
\*Correspondence to: Line Lisbeth Olesen, M.D., Department of Cardiology, Zealand University Hospital, Sygehusvej 10, 4000, Roskilde, Denmark; Tel: 4540830421; E-mail: [llole@regionsjaelland.dk](mailto:llole@regionsjaelland.dk); [olesen.line@gmail.com](mailto:olesen.line@gmail.com)



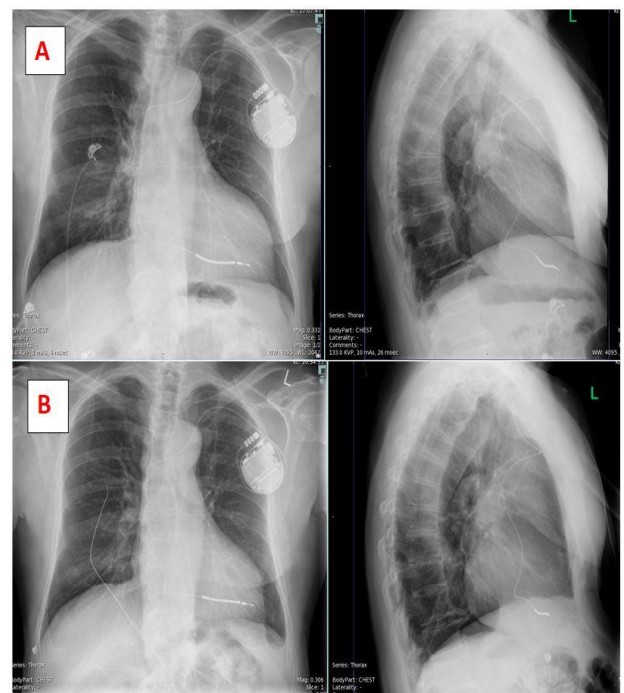
**Figure 1:** Case 1, Atrial fibrillation and ventricular pacing. **A)** ECG during cardiac tamponade demonstrating relative low voltage (compared to B) and pulsus paradoxus with variation in amplitude/electrical alternans and swinging baseline. **B)** ECG after resolution of the pericardial effusion.



**Figure 2:** Case 1, X-ray of thorax after implantation of ICD. **A)** On the way of the implantation. **B)** 3 weeks later. **C)** 6 weeks later. Gradually enlarging heart shadow and increasing distance from the tip of the electrode to the rim of the cardiac silhouette, corresponding to expanding pericardial effusion.



**Figure 3:** Case 1, Echocardiography. Pericardial effusion of 4 cm surrounding the heart. Fibrinous coating of the wall of the right ventricle. The ICD electrode lies in the right ventricle and the tip is secured on the septum (red circle).



**Figure 4:** Case 2, **A)** The day the ICD was implanted. **B)** The following day: the electrode has straightened and moved- and perforated apex of the right ventricle to the pericardial sac.

## Case-2

A 70-year-old male had a secondary prophylactic VVI-ICD implanted due to ischemic heart disease, VT, and syncope. The electrode was secured in the apex of the right ventricle. The surgeon reported no problems. BMI was 25. Two days after the surgical procedure he was readmitted due to severe back and chest pain worsening with respiration. Loss of capture and accentuation of the pain during pacing was observed. Based on the clinical picture and the pacemaker test it was concluded that the electrode had probably perforated the cardiac wall. ECG was unchanged. Chest X-ray not diagnostic (Figure 4). Fluoroscopy confirmed that the electrode had perforated several centimeters through the apex of the right ventricle to the pericardial sac between the base of the heart and the diaphragm. No pericardial effusion was found. The electrode was replaced without complications, still without pericardial effusion. No further problems were encountered.

## Discussion

The risk of cardiac perforation is higher with insertion of an ICD electrode than with an ordinary pacemaker electrode [3-8]. The electrode should be fixed with caution. Other risk factors are female gender, BMI<20, age>80 years, corticosteroid treatment, anticoagulation, platelet therapy, restless patient, inexperienced surgeon, over screwing of the electrode, excessive pressure on the electrode during fixation, and excessive electrode loop [2-4, 8-11]. None of these risk factors was present in neither case 1, nor case 2.

Perforation is a risk when the electrode is secured in the free wall or in the apex which is relative thin walled, as in case 2. Instead, the surgeon should attempt to fix the electrode on the septum, as in case 1 [1, 3, 8]. In addition to this, there is an increased risk of perforation when one electrode is replaced by another (as in case 1) when repeated repositioning of the electrode is necessary (as in case 1) and in patients with a thin-walled dilated cardiomyopathy (as in case 1) or ischemic cardiomyopathy (as in case 2) [8].

In case 1, a perforation occurred while checking for a good lead position, not when the lead was positioned on the septum. Therefore, lead replacement was not necessary. Slow accumulation of pericardial fluid allowed the collection of a large effusion in weeks before a significant increase in the pericardial pressure caused symptoms and signs. After treatment of the tamponade by drainage of the pericardial effusion, there were no more significant events. Pericardial bleeding is a trigger for the immune-mediated inflammatory post-cardiac injury syndrome (PCIS), which is difficult to differentiate from simple mechanical consequences of surgery. PCIS is associated with elevated CRP, as in case 1 [2, 12].

In patient 2, the perforation happened at the typical site, in the apex of the right ventricle. This patient had no pericardial effusion but pericardial irritation with severe pain accentuated by respiratory movements and by pacing. The pacemaker had no capture in the heart but there was painful extracardiac pacing. Despite perforation, the pacemaker values may remain normal; otherwise, the typical finding is an increase in the threshold or loss of capture, as in this case, or inappropriate shock [2-8, 11].

The two cases illustrate typical symptoms and consequences of perforation. The diagnostic gold standard is gated CT, which has optimal demarcation of the interface between the myocardium, blood and fat, although star artefacts from the pacemaker wire sometimes make it difficult to precisely identify the tip of the lead. Fluoroscopy, chest radiography, and echocardiography are not as reliable to diagnose perforation of the heart, as in case 2 where perforation was diagnosed from the clinical picture and ICD-failure with loss of capture [2-5, 7, 11, 13-15]. In acute and subacute perforation, transvenous lead extraction is possible without any difficulties, as in case 2. However, extraction demands hemodynamic and echocardiographic monitoring and preparedness to perform pericardiocentesis and surgical extraction [3-9, 11].

## Conflicts of Interest

None.

## Funding

None.

## REFERENCES

1. Vanezis AP, Prasad R, Andrews R (2017) Pacemaker leads and cardiac perforation. *JRSM Open* 8: 2054270416681432. [[Crossref](#)]
2. Ohlow MA, Lauer B, Brunelli M, Geller JC (2013) Incidence and Predictors of Pericardial Effusion After Permanent Heart Rhythm Device Implantation – Prospective Evaluation of 968 Patients. *Circ J* 77: 975-981. [[Crossref](#)]
3. Kumar S, Yassin H, Esan O, Budzikowski AS, Kassotis JT (2012) Mechanism and Management of Pacing Lead Related Cardiac Perforation. *Intech Open*.
4. Banaszewski M, Stepinska J (2012) Right heart perforation by pacemaker leads. *Arch Med Sci* 8: 11-13. [[Crossref](#)]
5. Hirschl DA, Jain VR, Spindola Franco H, Gross JN, Haramati LB (2007) Prevalence and Characterization of Asymptomatic Pacemaker and ICD Lead Perforation on CT. *Pacing Clin Electrophysiol* 30: 28-32. [[Crossref](#)]
6. Mori H, Kato R, Ikeda Y, Tsutsui K, Hasegawa S et al. (2020) Percutaneous Simple Lead Traction Is a Feasible and Effective Method for Right Ventricular Lead Perforations. *Int Heart J* 61: 54-59. [[Crossref](#)]
7. Balabanoff C, Gaffney CE, Ghersin E, Okamoto Y, Carrillo R et al. (2014) Radiographic and electrocardiography-gated noncontrast cardiac CT assessment of lead perforation: Modality comparison and interobserver agreement. *J Cardiovasc Comput Tomogr* 8: 384-390. [[Crossref](#)]
8. Migliore F, Zorzi A, Bertaglia E, Leoni L, Siciliano M et al. (2014) Incidence, Management, and Prevention of Right Ventricular Perforation by Pacemaker and Implantable Cardioverter Defibrillator Leads. *Pacing Clin Electrophysiol* 37: 1602-1609. [[Crossref](#)]
9. Zhou X, Ze F, Li D, Li XB (2018) Percutaneous management of atrium and lung perforation: A case report. *World J Clin Cases* 7: 4327-4333. [[Crossref](#)]
10. Vamos M, Erath JW, Benz AP, Bari Z, Duray GZ et al. (2017) Incidence of Cardiac Perforation With Conventional and With Leadless

- Pacemaker Systems: A Systematic Review and Meta-Analysis. *J Cardiovasc Electrophysiol* 28: 336-346. [[Crossref](#)]
11. Piekarz J, Lelakowski J, Rydlewska A, Majewski J (2012) Heart perforation in patients with permanent cardiac pacing – pilot personal observations. *Arch Med Sci* 8: 70-74. [[Crossref](#)]
  12. Adler Y, Charron P, Imazio M, Badano L, Baron Esquivias G et al. (2015) 2015 ESC Guidelines for the Diagnosis and Management of Pericardial Diseases: The Task Force for the Diagnosis and Management of Pericardial Diseases of the European Society of Cardiology (ESC) Endorsed By: The European Association for Cardio-Thoracic Surgery (EACTS) *Eur Heart J* 36: 2921-2964. [[Crossref](#)]
  13. Ahlert D, Mitchell ARJ (2019) Delayed presentation of right ventricular lead perforation following defibrillator implantation: a case report. *Eur Heart J Case Rep* 3: ytz121. [[Crossref](#)]
  14. Akbarzadeh MA, Mollazadeh R, Sefidbakht S, Shahrzad S, Bafruee NB (2017) Identification and management of right ventricular perforation using pacemaker and cardioverter-defibrillator leads: A case series and mini review. *J Arrhythmia* 33: 1-5. [[Crossref](#)]
  15. Rajkumar CA, Claridge S, Jackson T, Behar J, Johnson J et al. (2017) Diagnosis and management of iatrogenic cardiac perforation caused by pacemaker and defibrillator leads. *Europace* 19: 1031-1037. [[Crossref](#)]