

Available online at [www.sciencerepository.org](http://www.sciencerepository.org)

Science Repository



## Case Report

# Lipomodelling of the Breast Following Excision of a Giant Juvenile Fibroadenoma

Z Al-Ishaq<sup>1\*</sup>, Oishi Sikdar<sup>2</sup>, Meghna Roy<sup>3</sup>, A Bhatnagar<sup>4</sup> and T Sircar<sup>1</sup>

<sup>1</sup>General Surgery Department, Breast Unit, New Cross Hospital, The Royal Wolverhampton NHS Trust, Wolverhampton, UK

<sup>2</sup>Imperial College School of Medicine, London, UK

<sup>3</sup>Medical School, University of Birmingham, Birmingham, UK

<sup>4</sup>Histopathology Department, New Cross Hospital, The Royal Wolverhampton NHS Trust, Wolverhampton, UK

### ARTICLE INFO

#### Article history:

Received: 29 July, 2020

Accepted: 13 August, 2020

Published: 22 August, 2020

#### Keywords:

Giant

fibroadenoma

lipomodelling

breast

### ABSTRACT

Giant juvenile fibroadenomas form 1-8% of breast lesions in the adolescent population. We report a case of giant fibroadenoma in a 17-year-old girl who underwent simple lump excision through a lateral breast fold incision followed by lipomodelling to correct the dimpling of the breast. With this dual approach, excellent cosmetic outcome can be achieved for average-sized giant fibroadenoma without the need for more complex technique.

© 2020 Z Al-Ishaq. Hosting by Science Repository.

## Introduction

Giant juvenile fibroadenomas form 1-8% of breast lesions in the adolescent population. A juvenile fibroadenoma is deemed 'giant' if it has a mass of greater than 5cm, 500 grams, or replaces over 80% of the breast. Whilst there is a lot of literature on the subject and surgery remains the typical method of treatment, a consensus has not been reached in how best to achieve a desirable cosmetic outcome following surgical excision. The surgical treatment varies from simple enucleation of the lump to performing some form of reduction mammoplasty in order to achieve a good aesthetic outcome. This case demonstrates that for a giant juvenile fibroadenoma of average size an excellent cosmetic outcome can be achieved using a cosmetically placed lateral incision without any skin excision and allowing time for the skin to shrink, followed by lipomodelling of the breast to correct any residual dimpling. This case seems to be the first documentation of this dual approach for achieving a desirable aesthetic outcome.

## Case Presentation

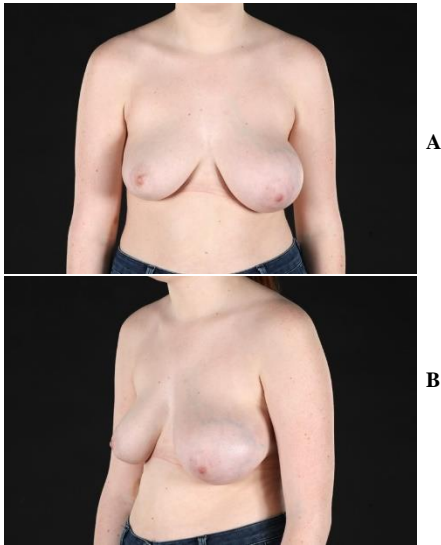
A 17-year-old girl presented with a gradual increasing size lump in her left breast, which she had noticed for 2-3 months (Figures 1A & 1B). She had no skin changes or other constitutional symptoms. There was no significant family history of breast cancer or ovarian cancer. On examination, there was obvious breast asymmetry with the left breast larger than the right. There was a large palpable lump occupying the upper and outer quadrant of the left breast. The right breast was normal and there were no other clinical abnormalities.

## Investigations

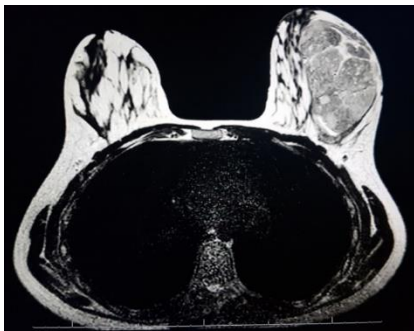
Ultrasound scan of the left breast showed two lesions in the upper and outer quadrant. The superior lesion measured 11 x 7 cm and the inferior 9.8 x 7 cm. Both lumps had solid and cystic areas suggestive of a giant fibroadenoma. Radiologically a phylloides tumor could not be excluded. An ultrasound-guided biopsy of both the lumps was performed which showed features of fibroadenoma but no evidence of phylloides tumor or malignancy. An MRI scan was carried out to determine the size and location of the lump and also its relationship with the rest of the breast tissue to help with the planning of surgery. The MRI scan revealed a

\*Correspondence to: Z Al-Ishaq, General Surgery Department, Breast Unit, New Cross Hospital, The Royal Wolverhampton NHS Trust, Wolverhampton, UK; E-mail: [zaid.al-ishaq@nhs.net](mailto:zaid.al-ishaq@nhs.net)

single large lump occupying nearly half of the upper outer breast (Figure 2) and stretching the overlying skin. The lump measured 11cm x 9cm.



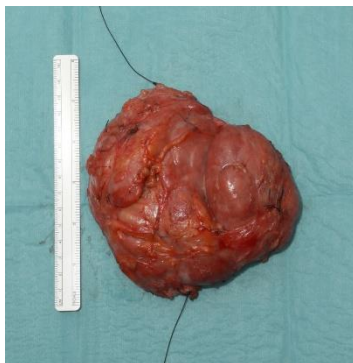**Figure 1:** At time of presentation.



**Figure 2:** MRI breast.

### Differential Diagnosis

- i Giant fibroadenoma.
- ii Physiologic hypertrophy.
- iii Phylloides tumor/malignancy.



**Figure 3:** Excised left breast lump.

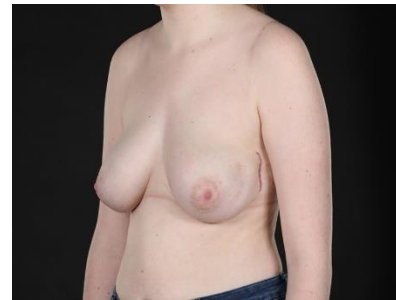### Treatment

The patient was informed of the potential risks and complications of the surgery, including dimpling at the site of the lump. With a lateral breast fold skin incision, the large lump was removed successfully. The

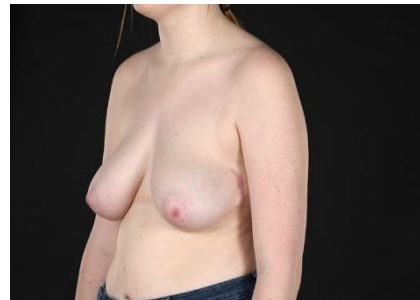overlying skin and the surrounding breast tissue were preserved. The lump (Figure 3) weighed 352 grams and measured 14.5cm x 13.4 cm. The histopathological evaluation confirmed juvenile fibroadenoma and showed a fibroepithelial lesion with cellular stroma and usual hyperplasia with no evidence of stromal overgrowth or hypercellularity or excessive mitosis.

### Outcome and Follow-Up

The patient tolerated the operation well with no significant complications. At 3 months, there was slight residual dimpling in the upper and outer quadrant of the left breast (Figure 4). Subsequently this dimpling was corrected by lipomodelling with 15mls of the autologous fat graft (Figure 5).



**Figure 4:** 3 months after excision of the left breast lump showing dimpling in the upper outer quadrant.



**Figure 5:** 3 months after lipomodelling to the left breast.

### Discussion

Fibroadenomas are benign breast masses which typically present in young women during adolescence. They are the most common type of breast tumor amongst this age group and are termed juvenile fibroadenoma [1]. A juvenile fibroadenoma is defined as giant if it has a mass of greater than 5cm, 500 grams or replaces over 80% of the breast. Giant juvenile fibroadenomas are less common than fibroadenomas and comprise 1-8% of breast lesions in the adolescent population [2, 3]. The aetiology is believed to be increased stimulation of oestrogens and/or end-organ hypersensitivity or decreased level of progesterone [4].

Giant juvenile fibroadenomas usually manifest as breast asymmetry or deformity and are typically unilateral [5]. They have a tendency to grow rapidly which may result in pain, discomfort, breast deformity and anxiety prior to diagnosis. Most present as a solitary lesion but there are cases of multiple masses requiring attention. The majority of giant fibroadenoma are diagnosed using ultrasonography while the use of mammography is limited because of increased breast density in this age group [6, 7]. In our case, we performed an MRI scan of the breast to

define the exact size and location of the lump and also to help in surgical planning. Histological diagnosis is usually done by pre-operative core needle biopsy [1, 4, 8].

Standard treatment of giant fibroadenoma is surgical resection though according to one report complete tumor regression may occur naturally over time in 10 – 59% of lesions [1]. There is no consensus in the literature about the surgical management of giant fibroadenoma [9]. Surgical resection is recommended in patients with breast deformity or those who have local mass effects like venous congestion, pressure necrosis and even ulceration [10]. In order to achieve superior aesthetic results an emphasis on preserving the developing breast parenchyma and nipple-areolar complex is of great importance [6].

Various surgical techniques have been reported in the literature. While some authors recommended simple enucleation of the mass using appropriately sited peri-areolar or inframammary cosmetic incision relying on the remaining displaced breast tissue to fill in the space left by the excised giant fibroadenoma so negating the need for reconstruction, others advised the use of mastopexy or reduction mammoplasty technique using the inverted T-incision technique [4, 9, 11-16]. Achebe *et al.* considered significant breast asymmetry, i.e., the difference in the position of the nipple areola complex of 6 cm, as an indication for reduction mammoplasty [17]. In some cases of larger fibroadenoma, an adapted version of the Goldilock's technique had been used successfully [18]. At 5-year follow up, the literature has reported about 33% risk of recurrence after excision of the giant fibroadenomas [19].

Although most of the literature advocate a breast conservative approach, mastectomy has been reported rarely for patients with unusual or recurrent giant fibroadenoma [1, 10]. Following mastectomy, especially in young patients, breast reconstruction using either prosthesis or autologous tissue should be considered to decrease the psychological trauma [20]. To the best of our knowledge, this is the first case of giant juvenile fibroadenoma that has been treated with simple enucleation through a cosmetically sited lateral incision followed by lipomodelling of the resultant skin dimpling post-surgery. Delay E *et al.* has reported the use of fat transfer to correct moderate sequelae of breast-conservative surgery and described it as superior to any other surgical techniques to correct mild breast deformity as it restores breast shape and softness [21]. Ho Quoc C *et al.* recommended lipomodelling to correct breast malformations as well, for instance tuberous breast [22].

Our case was typical of a giant juvenile fibroadenoma with the patient being within the adolescent age group and presenting with a unilateral solitary lump. Ultrasound scan suggested that there were two lumps. MRI scan was performed to give accurate information about the size and location of the lump and its relationship to the rest of the breast tissue and overlying skin as mammogram is not helpful in this age group due to the increased density of the breast tissue. The MRI scan was helpful in our case to know that it was a single large lump measuring 11cm x 9cm, occupying nearly half of the upper outer breast (Figure 3) and the overlying skin had a good amount of subcutaneous fatty tissue.

The lump was too big to be removed through a circumareolar incision. In order to avoid any incision on the breast surface and also achieve an excellent cosmetic outcome a novel approach of using a cosmetically

placed lateral fold incision without any skin excision was adopted. This allowed the skin to contract postoperatively and the remaining displaced breast tissue filled the space left by the excised giant fibroadenoma thereby negating the need for more invasive procedures like mammoplasty. We expected that there would be some dimpling post operatively. In fact, at 3 months, the dimpling was very slight. This was corrected with 15mls of autologous fat grafting (lipomodelling). Overall, this combined approach achieved an excellent cosmetic result for the patient.

## Conclusion

Simple lump excision through a cosmetically placed incision followed by lipomodelling can achieve an excellent cosmetic outcome for moderately large giant fibroadenoma without the need for complex mammoplasty operations.

## REFERENCES

1. Michael Sosin, Marisa Pulcrano, Elizabeth D Feldman, Ketan M Patel, Maurice Y Nahabedian et al. (2015) Giant juvenile fibroadenoma: a systematic review with diagnostic and treatment recommendations. *Gland Surg* 4: 312-321. [[Crossref](#)]
2. Yasmin Jayasinghe, Patricia S Simmons (2009) Fibroadenomas in adolescence. *Curr Opin Obstet Gynecol* 21: 402-406. [[Crossref](#)]
3. Madhumita Mukhopadhyay, Rishavdeb Patra, Sima Mondal, Asit Ghosh, A K Ray (2009) Bilateral giant juvenile fibroadenoma of breasts. *J Indian Assoc Pediatr Surg* 14: 68-69. [[Crossref](#)]
4. Aris Giannos, Sofoklis Stavrou, Christina Gkali, Eleni Chra, Spyridon Marinopoulos et al. (2017) A prepubertal giant juvenile fibroadenoma in a 12-year-old girl: Case report and brief literature review. *Int J Surg Case Rep* 41: 427-430. [[Crossref](#)]
5. U Hille Betz, R Klapdor, H Henseler, P Soergel, F Länger (2015) Treatment of Giant Fibroadenoma in Young Women: Results after Tumor Excision without Reconstructive Surgery. *Geburtshilfe Frauenheilkunde* 75: 929-934. [[Crossref](#)]
6. P S Simmons (1992) Diagnostic considerations in breast disorders of children and adolescents. *Obstet Gynecol Clin North Am* 19: 91-102. [[Crossref](#)]
7. C Templeman, S P Hertweck (2000) Breast disorders in the pediatric and adolescent patient. *Obstet Gynecol Clin North Am* 27:19-34. [[Crossref](#)]
8. Prakasit Chirappapha, Panuwat Lertsithichai, Thongchai Sukarayothin, Monchai Leesombatpaiboon, Chairat Supsamutchai et al. (2016) Oncoplastic techniques in breast surgery for special therapeutic problems. *Gland Surg* 5: 75-82. [[Crossref](#)]
9. Andrea Hiller, Thomas J Lee, Joshua Henderson, Nicolas Ajkay, Bradon J Wilhelmi (2018) Oncoplastic Reduction Pattern Technique Following Removal of Giant Fibroadenoma. *Eplasty* 18: e4. [[Crossref](#)]
10. Christopher A Park, Lisa R David, Louis C Argenta (2006) Breast asymmetry: presentation of a giant fibroadenoma. *Breast J* 12: 451-461. [[Crossref](#)]
11. Brian D Biggers, Jeff P Lamont, Chukwuemeka N Etufugh, Sally K Knox (2009) Inframammary approach for removal of giant juvenile fibroadenomas. *J Am Coll Surg* 208: e1-e4. [[Crossref](#)]
12. M M Jacob (2000) Application of reduction mammoplasty in treatment of giant breast tumour. *Br J Plast Surg* 53: 265-266. [[Crossref](#)]

13. Michael Sosin, Elizabeth Feldman (2012) Giant juvenile fibroadenoma: a case and review of novel modalities in treatment. *Breast Dis* 34: 35-38. [[Crossref](#)]
14. Y Yamamoto, T Sugihara (1998) Application of reduction mammoplasty in treatment of giant breast tumour. *Br J Plast Surg* 51: 109-112. [[Crossref](#)]
15. M Daya, O Mahomva, A Madaree, K Conwright (2003) Reduction mammoplasty in cases of giant fibroadenoma among adolescent females. Case reports and literature review. *S Afr J Surg* 41: 39-43. [[Crossref](#)]
16. M Daya, T Balakrishnan (2018) Surgery for giant tumours of the breast: a 15 year review. *S Afr J Surg* 56: 9-15. [[Crossref](#)]
17. J U Achebe, G E Njeze, O R Okwesili (2014) Treatment of unilateral giant fibroadenoma by breast reduction skin incision: the inverted "T" technique. *Niger J Clin Pract* 17: 43-46. [[Crossref](#)]
18. Ryan P Ter Louw, Sara B Bruce, Maurice Y Nahabedian (2017) Partial Breast Reconstruction with Goldilocks Technique After Excision of Giant Fibroadenoma: A Case Report. *Plast Reconstr Surg Glob Open* 5: e1200. [[Crossref](#)]
19. Bong Sup Song, Eun Kyu Kim, Hyesil Seol, Jun Hee Seo, Jun Ah Lee et al. (2014) Giant juvenile fibroadenoma of the breast: a case report and brief literature review. *Ann Pediatr Endocrinol Metab* 19: 45-48. [[Crossref](#)]
20. Davorin Kozomara, Nikica Šutalo, Gordan Galić, Sanja Jurišić, Zoran Trninć (2016) Giant unilateral breast juvenile fibroadenoma - the aesthetic outcome of surgical treatment should be considered. *Psychiatr Danub* 28: 256-259. [[Crossref](#)]
21. E Delay, J Gosset, G Toussoun, T Delaporte, M Delbaere (2008) Efficacy of lipomodelling for the management of sequelae of breast cancer conservative treatment. *Ann Chir Plast Esthet* 53: 153-168. [[Crossref](#)]
22. C Ho Quoc, J M Piat, G Michel, C Dlimi, S La Marca (2015) Fat grafting to improve severe tuberous breast. *J Gynecol Obstet Biol Reprod* 44: 503-509. [[Crossref](#)]